

CYSTIC NEOPLASMS OF THE PANCREAS: CT AND SONOGRAPHY

Janjira JATCHAVALA¹, Sirintara PONGPECH¹,
Patchrin PEKANAN¹, Ratanaporn PORNKUL¹, Churirat KULARBKAEW².

ABSTRACT

Cystic neoplasms of the pancreas were pathologically divided into two major groups: microcystic adenomas and mucinous cystic neoplasms. Early diagnosis and differentiation from other pancreatic lesions were essential for appropriate management. Two cases of mucinous cystadenomas, one case of mucinous cystadenocarcinoma and one case of microcystic cystadenoma were presented and the sonographic and computed tomographic features were compared. The differential diagnosis were discussed.

Cystic neoplasms of the pancreas are relatively rare ; accounting for 5 to 15% of pancreatic cystic lesions and less than 5% of pancreatic tumors (1). Pancreatic cystic neoplasms are mainly classified into two categories, microcystic adenoma and mucinous cystic neoplasm (2,3). The mucinous cystic neoplasms are subdivided into mucinous (macrocytic) cystadenoma and mucinous (macrocytic) cystadenocarcinoma. Preoperative diagnosis is important because microcystic cystadenoma is benign, thus asymptomatic case does not usually require surgical resection. Mucinous cystadenoma is potentially or overtly malignant.

We presented 4 cases of cystic neoplasms, including two mucinous cystadenomas, one mucinous cystadenocarcinoma and one microcystic cystadenoma. The purpose was to illustrate sonographic and computed tomographic findings of these tumors and assess the advantage of each modality. The differential diagnosis of the tumors from other pancreatic lesions were discussed.

CASE REPORTS

CASE 1.

A 18 year-old female presented with left upper abdominal pain radiating to left shoulder and back for 8 months. There was nausea without vomiting and no history of trauma. Upper G.I. series revealed a retrogastric mass (Fig. 1A). Sonogram showed a large cystic mass located in the tail of pancreas with thin septae throughout the mass, measuring 5×5×6 cm. (Fig. 1B). CT scan showed a well defined mass with characteristic Hounsfield units in the range of water (Fig. 1C,D). The septations noted on sonography were difficult to appreciate. At surgery, the mass was removed along with the spleen. Gross specimen showed an irregular cavity about 4×3×3 cm. in size, containing multiloculated thin-walled cysts about 2.5 cm. in diameter. The diagnosis was mucinous cystadenoma.

¹ Department of Radiology, Ramathibodi Hospital, Rama 6 Street, Bangkok 10400, Thailand.

² Department of Pathology, Srinagarin Hospital, Khon Kaen, Thailand.

CASE 2

A 32 year-old female presented with abdominal mass and dyspepsia for 2 months. An approximately 4 cm. in diameter, movable mass at mid epigastrium was noted on physical examination. Sonogram revealed a low echoic mass about 6 cm, in diameter at tail of pancreas with internal septations and slightly smooth thick wall (Fig. 2A). CT scan showed a cystic mass located between body and tail of pancreas, measuring 5×4 cm. There was pressure effect to inferior surface of left lobe liver (Fig. 2B,C). No lymphadenopathy or evidence of pancreatic tail atrophy was noted. At surgery, a well circumscribed cyst was found at the tail of pancreas. Distal pancreatectomy and splenectomy was performed. Gross specimen showed a multiloculated cyst about 4 cm. in largest diameter at posterior aspect of proximal part of pancreatic body. The inner surface of the wall was irregular with small areas of golden yellow soft tissue. Histology indicated mucinous cystadenoma.

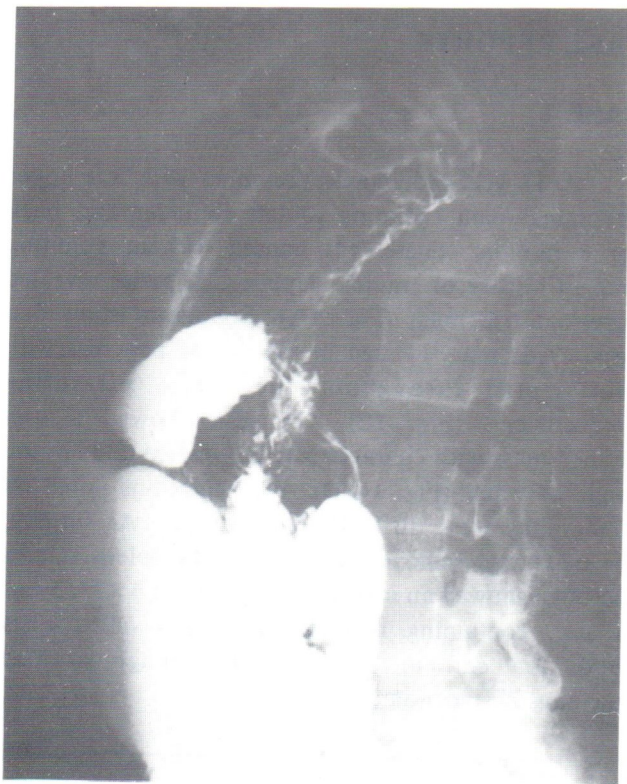


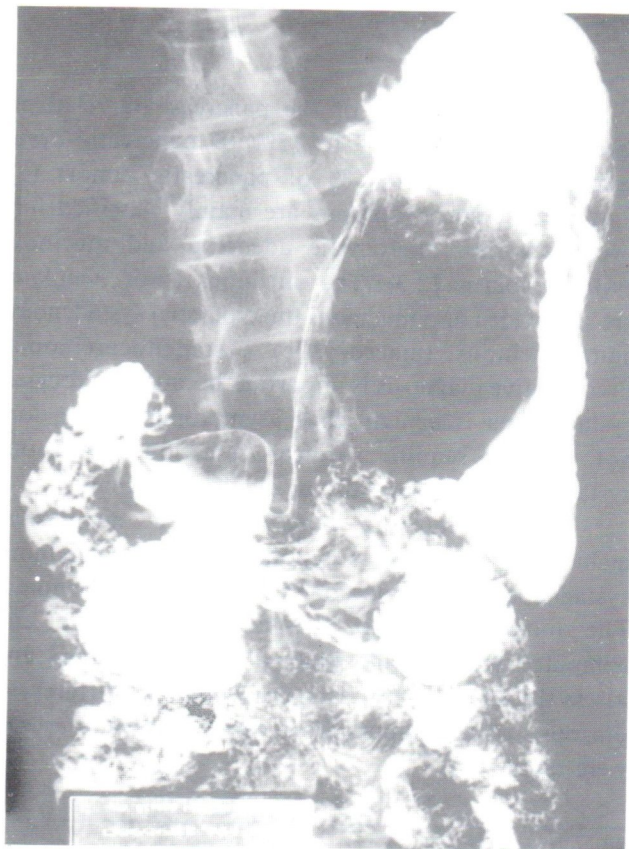Fig. 1A Case 1 Mucinous cystadenoma. Upper GI series showed a large retrogastric mass.

CASE 3

A 40 year-old female presented with a movable, and tender left upper quadrant mass. It was progressively enlarged for 7 months. An IVP study showed a retroperitoneal mass displacing left kidney inferomedially (Fig. 3A). Sonogram revealed a large cystic mass in the tail of pancreas containing fine and homogeneous internal echoes (Fig. 3B). CT scan showed a well-circumscribed cystic mass, size about 10×10×9 cm. Small mural projection was seen in the superior aspect of the mass (Fig. 3C,D). The patient underwent distal pancreatectomy and splenectomy. A cystic mass was found about 20-25 cm. in diameter. It contained chocolate-like content and papillary growth from its wall. The histology was mucinous cystadenocarcinoma.

CASE 4

A 75 year-old female, known case of Parkinsonism, presented with left upper abdominal



mass for 6 months. She had weight loss and low grade fever. Sonogram revealed a large mixed echogenic solid mass about 9 cm. in diameter, located at an anteromedial aspect to left kidney and likely to continue with the tail of pancreas (Fig. 4A). Non-contrast CT scan showed a large, lobulated cystic mass about $8 \times 9 \times 6$ cm in size, with foci of central calcification. Contrast study demonstrated enhanced septations and rim enhancement. The origin could not be definitely determined, it might arise from the anterior pararenal space involving pancreatic tail and body, or mainly from the pancreas itself. The mass

displaced the posterior wall of the stomach upward and the transverse colon downward (Fig. 4B,C). Gastroscope was normal. At surgery, there was a retroperitoneal mass about 15 cm. in diameter situated posterior to the lesser sac, adhering to the tail of pancreas. Distal pancreatectomy was performed. Gross specimen showed a large, multiloculated cystic mass, measuring $11 \times 8 \times 9$ cm. There were numerous small cysts separated by fibrous strands. The histologically verified a serous (microcystic) cystadenoma.

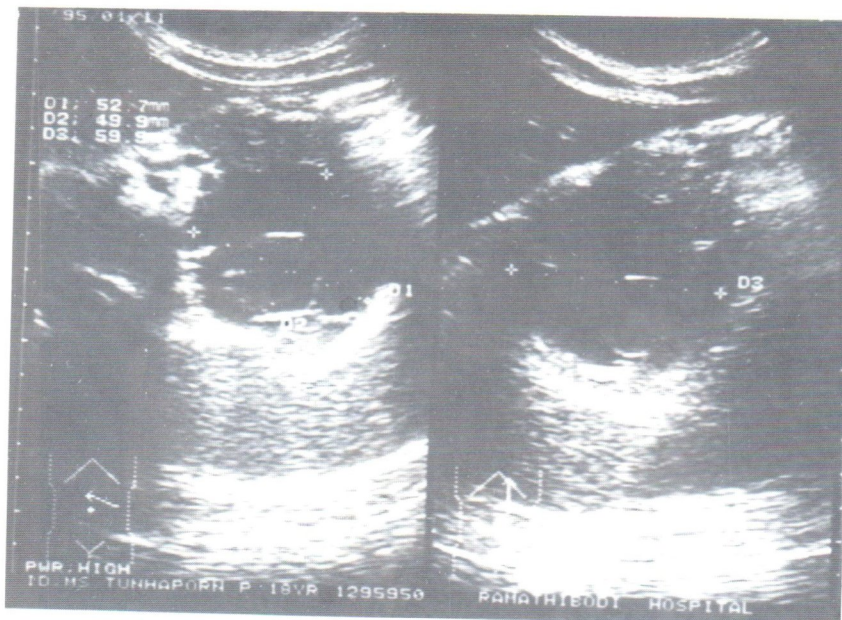


Fig. 1B Case 1 Ultrasound showed a large cystic mass located in the tail of pancreas with thin septae throughout the mass.

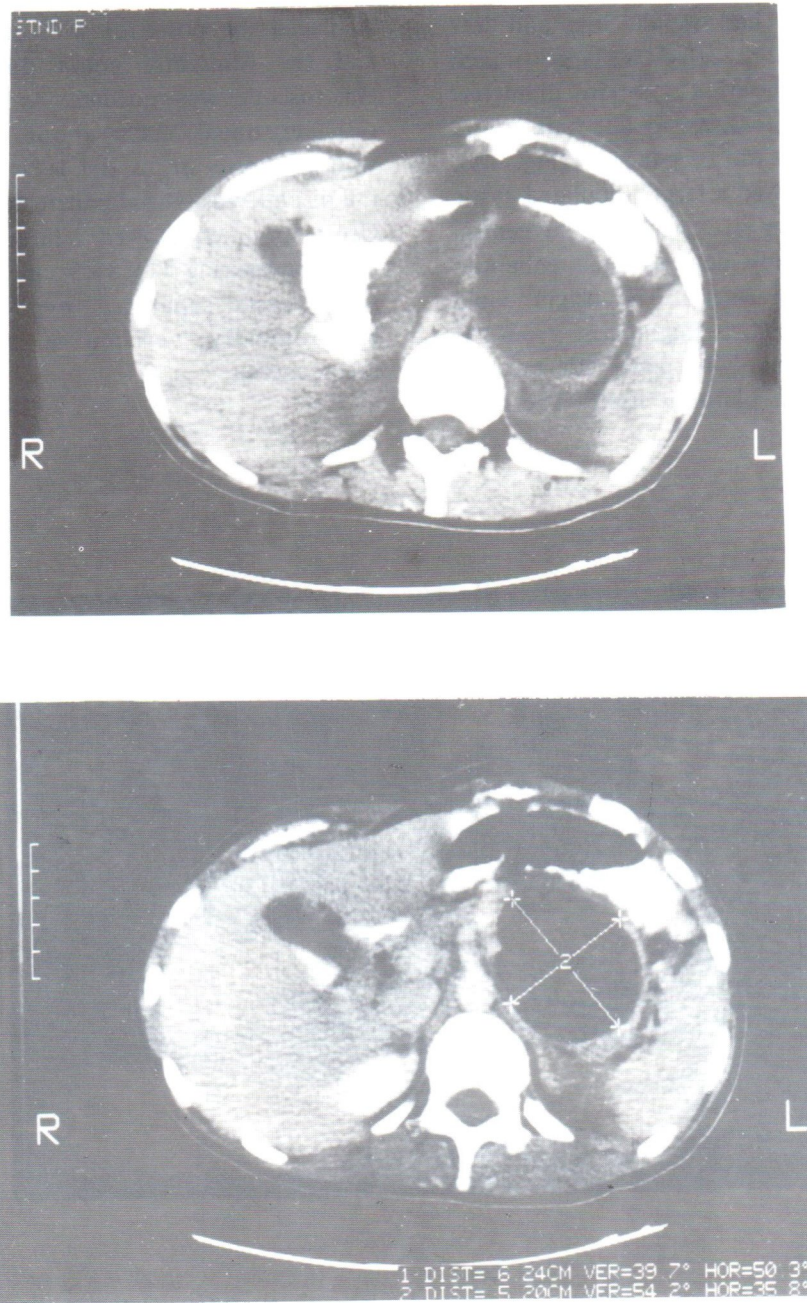


Fig. 1 C,D Case 1 C. Non-contrast CT scan showed a cystic mass at tail of pancreas
D. Contrast scan showed slightly enhanced wall, the septations were difficult to identify

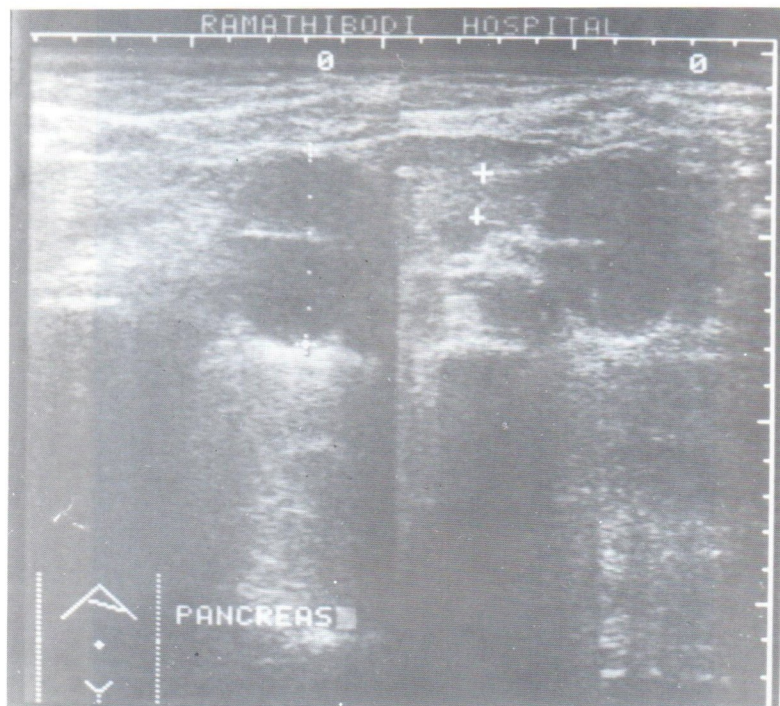


Fig. 2A Case 2 Mucinous cystadenoma
 Sonogram showed a low echoic mass at the tail of pancreas with internal septations and slightly smooth thick wall.

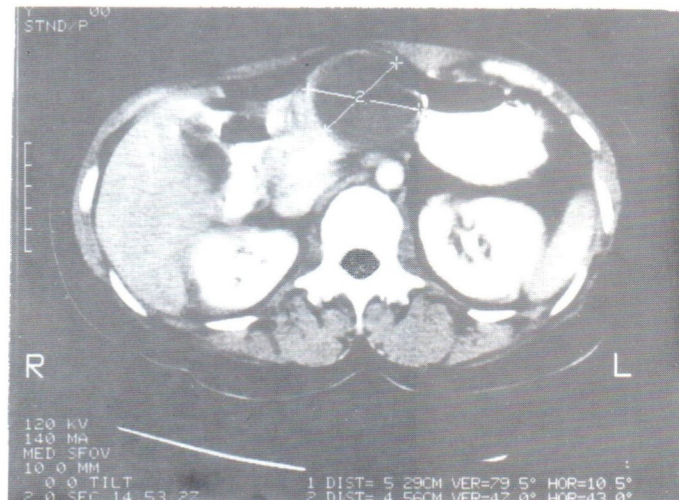
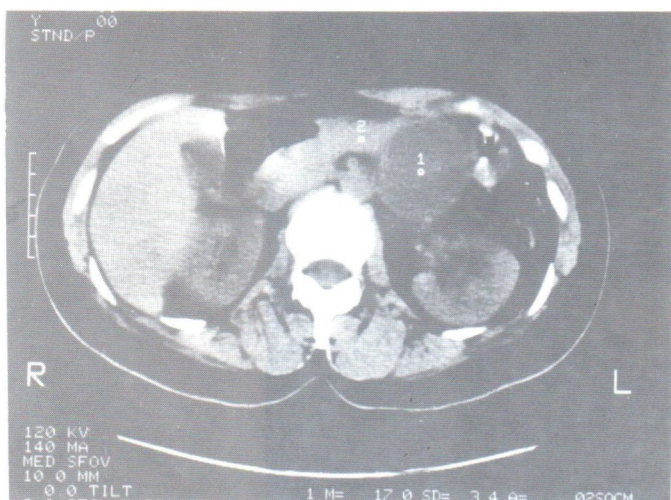


Fig. 2 B,C Case 2. B. Non-contrast CT scan showed a well defined cystic mass located between body and tail of pancreas.
 C. Contrast study showed slightly enhanced wall. Septations was not seen.

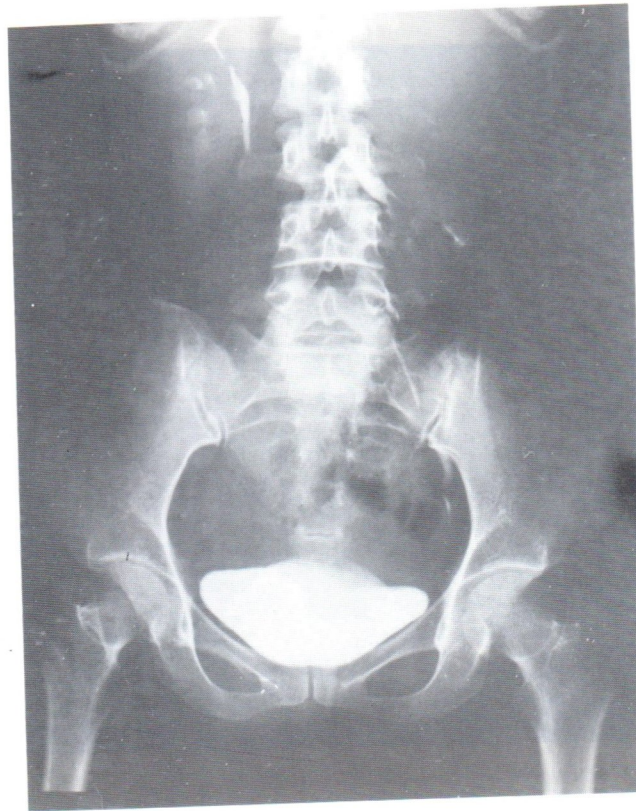


Fig. 3A. Case 3. Mucinous cystadenocarcinoma IVP showed a large retroperitoneal mass displacing left kidney inferomedially.

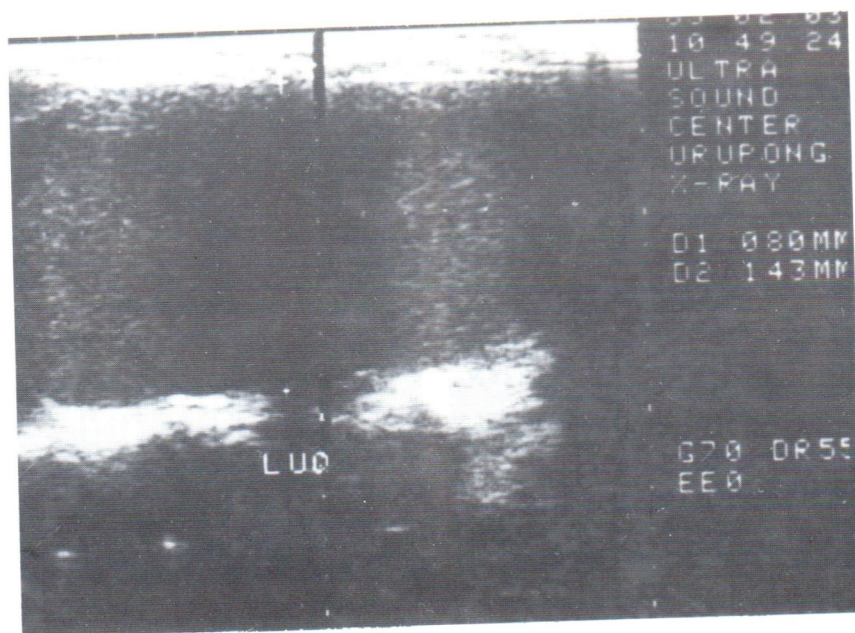


Fig. 3B Case 3. Sonogram showed a large cystic mass in the area of pancreatic tail. Homogeneous internal echoes were demonstrated.

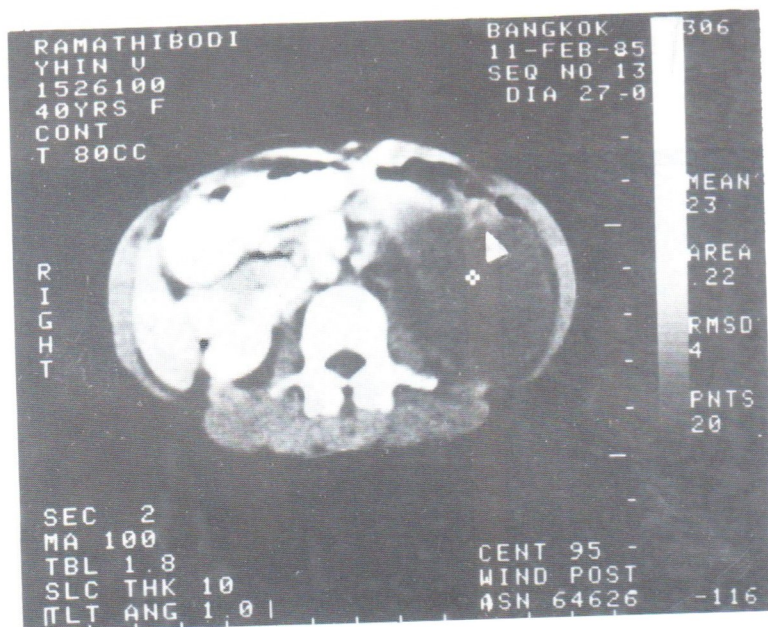
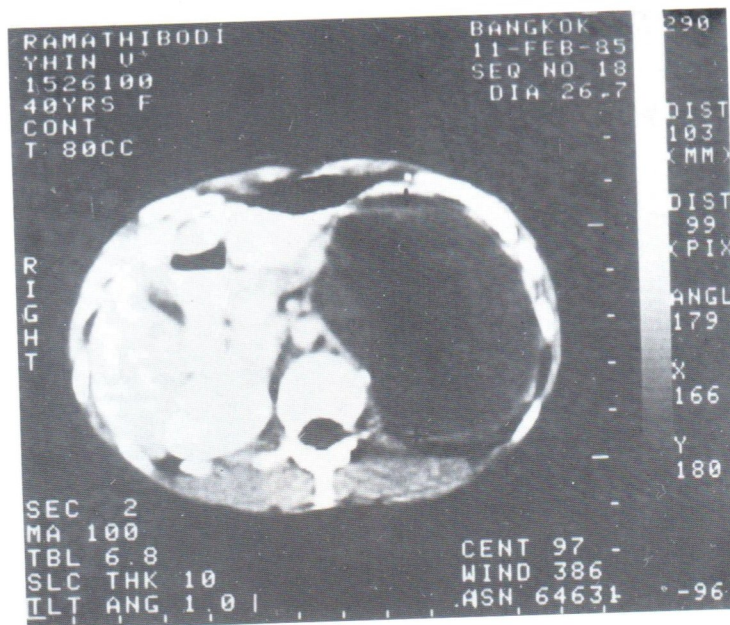


Fig. 3 C,D Case 3. Contrast study showed a cystic mass at the tail of pancreas. Small mural projection was seen at superior wall of the mass (arrowhead).

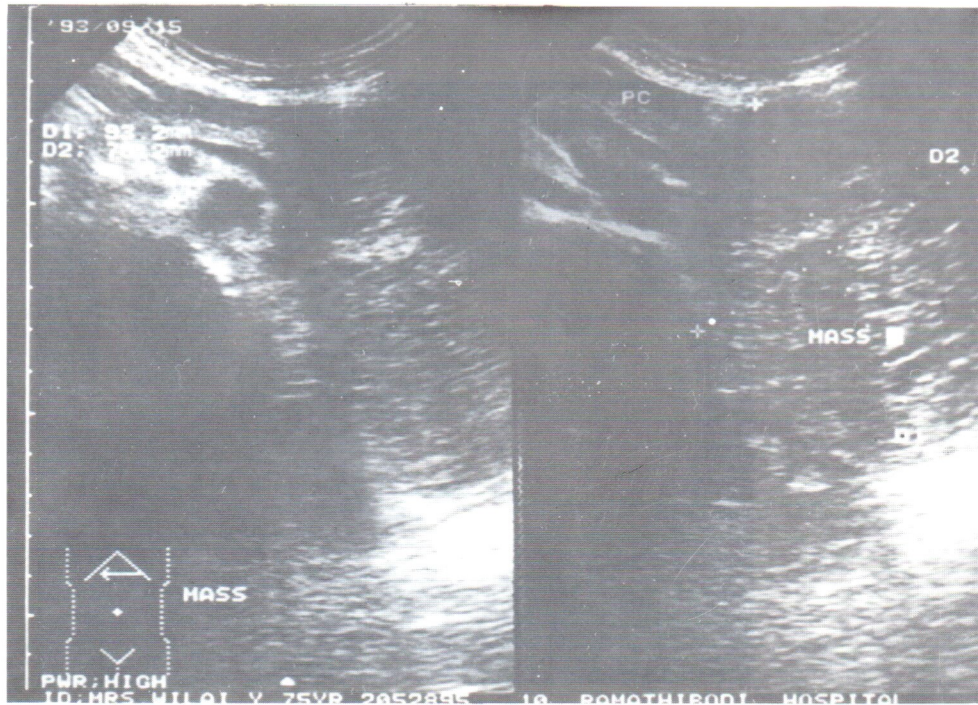


Fig. 4A Case 4 Microcystic cystadenoma.
A sonogram revealed a large mixed echogenic solid echo mass.

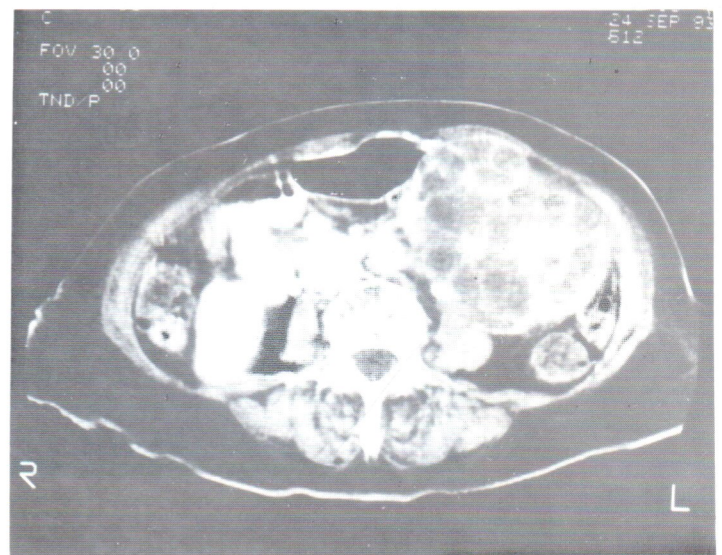
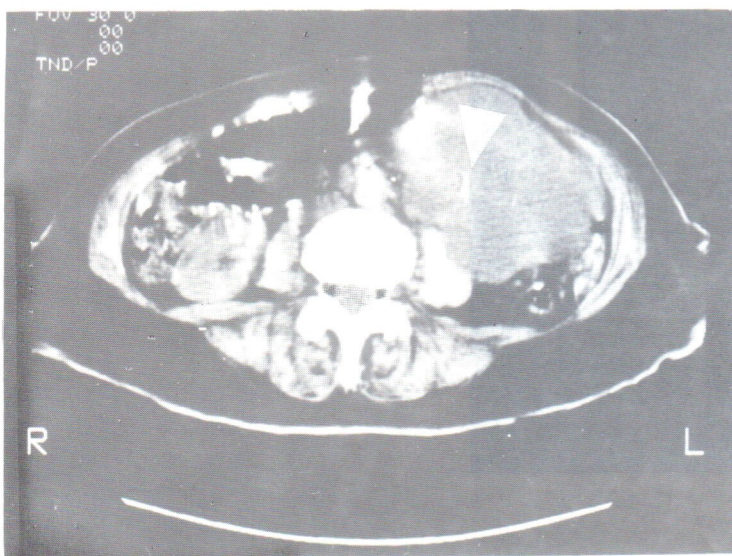


Fig. 4 B,C Case 4. B. Non-contrast study showed a large, lobulated cystic mass with foci of central calcification (arrow head)
C. Contrast study demonstrated enhanced septations and rim enhancement.

DISCUSSION

Compagno and Oertel classified the cystic pancreatic neoplasms into two groups; microcystic adenomas and mucinous cystic neoplasms, which include mucinous cystadenoma and mucinous cystadenocarcinoma (2,3).

The mucinous cystadenoma or cystadenocarcinoma typically was a smooth surfaced mass that was either unilocular or multilocular cysts more than 2 cm. in diameter and usually had dense fibrous walls with papillary projections. Their walls and septa sometimes had small calcification. The tumor prevailed in middle aged woman (average age 48 yrs., sex ratio 6:1) and located most frequently in the body and tail of pancreas (4-6). The lesion has a significant malignant potential. Surgical excision was the therapy of choice.

The microcystic adenomas typically had multiple (usually more than 6), small (usually less than 3 cm. in diameter) cysts. The tumor may contain a central stellate scar, sometimes associated with calcification (40% of cases) which was not seen in mucinous cystic neoplasm. The cysts contained glycogen-rich fluid. There was a 1.5:1 female predominance and occurred in elderly patient (average 68 years). The tumor could originate from any location in the pancreas. (4-6). In asymptomatic patient, surgery may not be required.

The CT and sonographic appearance of the cystic neoplasms can be explained on the basis of the primary morphologic difference in these tumors.

In two cases of mucinous cystadenomas, the sonogram showed classic anechoic cysts with enhanced through transmission and internal septations. CT scan showed a well circumscribed water density mass. The internal septa were faintly seen in case 1 and was not seen in case 2. Thus sonogram was better than CT scan in demonstration of septations. In case 3, mucinous cystadenocarcinoma, sonogram showed a cystic mass with internal echoes which may represent debris or hemorrhage. Mural projection was demonstrated by CT scan. CT scan in most cystadenocarcinomas were usually similar to that of mucinous cystadenomas except when invasion to adjacent organs or distant metastases was present. (5,7).

In the case of microcystic cystadenoma, sonogram showed a large mixed echogenic solid appearing mass at the tail of pancreas. The explanation for solid appearance of this tumor was not clear, may be due to the extremely small size of the cysts (4). CT scan could obviously demonstrate calcification in the central stellate scar. The septa were markedly

enhanced in contrast enhanced CT images, giving a honeycomb appearance.

A common differential diagnosis in these patients was pancreatitis with pseudocyst formation. Pseudocysts were unilocular, rounded masses whose wall was uniform in width and frequently located outside the pancreas and be found in patients with clinical and laboratory evidence of pancreatitis (8,9). Atypical pseudocysts containing hemorrhage and/or debris or those with septa or irregular wall might be difficult to distinguish from cystic tumor by sonogram (10). CT scan might be helpful by virtue of contrast enhanced solid portion of the tumor (11).

Pseudocysts or retention cysts might be found in associated with pancreatic cancer, they could simulate a cystic neoplasm (12). These cysts usually located between the solid tumor and the tail of pancreas. CT scan may show a solid mass consistent with pancreatic cancer and/or dilatation of the proximal pancreatic duct. The presence of septa or daughter cysts along the wall of a large cyst favored cystadenocarcinoma.

Some solid pancreatic cancers may show areas of very low density caused by tumor necrosis (13). The low density areas were usually irregular in shape and small in size, in comparison with the solid portion of tumor.

Islet-cell carcinomas and leiomyosarcomas of adjacent organs which had undergone central necrosis may appear as a unilocular or multilocular cysts with thickened wall (14), but the degree of contrast enhancement of these tumors may be greater than that of cystic pancreatic neoplasms.

The rare cystic tumors such as congenital cyst and lymphangioma might be unilocular or multilocular occurring in infant (15). Patients with von Hippel-Lindau disease had multiple small pancreatic cysts along with an increased incidence of pancreatic carcinoma (16). Cystic lymphangioma of the pancreas was very rare. It was a benign tumor origination from lymphatic vessels. CT scan revealed a cystic, multiloculated mass which was indistinguishable from pancreatic cystadenoma (17).

In conclusion, a correct preoperative diagnosis of cystic pancreatic neoplasm should be possible by a combination of the sonogram and CT scan. Knowledge of their radiologic and pathologic features, analysis of the number and size of cysts, could successfully subtype the tumors into benign microcystic adenomas or potentially malignant mucinous cystadenomas or cystadenocarcinomas.

REFERENCE

1. Cubilla LA, Fitzgerald PJ : Classification of pancreatic cancer (nonendocrine). Mayo clin Proc 1979;54:449-458.
2. Compagno J, Oertel JE : Microcystic adenomas of the pancreas (glycogen-rich cystadenomas) A clinico-pathologic study of 34 cases. Am J Clin Pathol 1978;69:289-298.
3. Compagno J, Oertel JE : Mucinous Cystic Neoplasms of the pancreas with overt and latent malignancy (cystadenocarcinoma and cystadenoma). Am J Clin Pathol 1978;69:573-580.
4. Wolfman NT, Ramquist NA, Karstaedt N, Hopkins MB. Cystic neoplasms of the pancreas: CT and sonography. AJR 1982;138:37-41.
5. Itai Y, Moss AA, Ohtomo K. Computed tomography of cystadenoma and cystadenocarcinoma of the pancreas. Radiology 1982;145:419-425.
6. Frideman AC, Lichtenstein JE, Dachman AH. Cystic neoplasms of the pancreas: radiologic-pathologic correlation. Radiology 1983;149:45-50.
7. Johnson CD, Stephen HD, Charboneau JW. Cystic pancreatic tumors : CT and Sonographic Assessment. AJR 1988;151:113-1138.
8. Becker WF, Welsh RA, Pratt HS. Cystadenoma and cystadenocarcinoma of the pancreas. Ann Surg 1965;161:845-860.
9. De Santos LA, Bernardino ME, Paulus DD, Martin RE. Computed tomography of cystadenoma of pancreas. J Computed Assist Tomogr 1978;2:222-225.
10. Laing FC, Gooding GAW, Brown T, Leopold GR. Atypical pseudocysts of the pancreas: an ultrasonographic evaluation. JCU 1979;7:27-33.
11. Araki T, Ohtomo K, Itai Y, Lio M. Demonstration of septa in cystic lesions : comparison study of computed tomography and ultrasound. Clin Radio 1982;33:325-329.
12. Itai Y, Moss AA, Goldberg HI. Pancreatic cysts caused by carcinoma of the pancreas : a pitfall in the diagnosis of the pancreatic carcinoma. J Comput Assist Tomogr 1982;6(4):772-776.
13. Kaplan JO, Ishifoff MB, Barkin J, Livingstone AS. Necrotic carcinoma of the pancreas: "the pseudo-pseudocyst". J Comput Assist Tomogr 1980;4:166-167.
14. Gold J, Rosenfield AT, Sostman D, Burrell M, Taylor KJW. Nonfunctioning islet cell tumors of the pancreas : radiographic and ultrasonographic appearances in two cases. AJR 1978; 131:715-717.
15. Mares AJ Hirsch M. Congenital cysts of the head of pancreas. J Pediatr Surg 1977;12:547-552.
16. Fill HL, Lamiell JM, Polk NO. The radiographic manifestation of von Hippel-Lindau disease. Radiology 1979;133:289-295.
17. Ignazio P, Emanuele S, Michele G, et al. Cystic Lymphangioma of the pancreas: CT Demonstration. J Comput Assist Tomogr 1985;9:209-213.

