

ABDOMINAL ACTINOMYCOSIS

Dr. Y Y Sitoh¹, Dr. T K Khoo²,

ABSTRACT

Actinomycosis is an infrequent intra-abdominal infection, mimicking and often mistaken for other diseases. We present a case of lower abdominal actinomycosis presenting as a mass lesion.

INTRODUCTION

Actinomycosis can affect multiple organs, with local or systemic presentations. While infection is most common in the cervico-facial area, abdominal actinomycosis accounts for about 20% of all cases.^{1,2} Though the typical CT features of multiple organ and anatomic compartment involvement with transfascial spread have been described,^{3,4} diagnosis remains difficult, especially in the abdomen.^{1,2} The correct diagnosis at presentation is obtained in less than 10% of cases.^{5,6}

CASE REPORT

A 25 year old Chinese female presented initially with colicky central abdominal pain and dysuria of one week's duration. Apart from equivocal tenderness at the right iliac fossa, the clinical examination was unremarkable. Urine microscopy was normal.

Clinical review a month later showed a suprapubic mass which appeared related to the uterus. She was otherwise well, urine pregnancy test was negative. Ultrasound showed a right iliac fossa mixed echogenicity mass, possibly related to bowel (Fig. 1); but unrelated to the gynaecological structures which

were normal. The bladder dome showed a fixed plaque of 9 mm thickness (Fig. 2), the nature of which could not be determined then. Some fluid within the pouch of Douglas was noted.

Further investigation with a barium enema revealed an extrinsic lesion in the region of the appendix, caecum and terminal ileum (Fig. 3,4). CT scan before and after intravenous contrast injection confirmed an enhancing soft tissue mass in the lower abdomen infiltrating the bladder dome (Fig. 5), and closely related to intestine. The involved bowel loops showed thickened walls (Fig. 6). There was loss of the normal fat plane between the bladder and uterus. No significant lymphadenopathy but considerable fluid in the pouch of Douglas was noted. The impression was of a malignant mass.

At laparotomy, omental cake of inflammatory tissue with sulphur granules involving intestine, bladder dome and the anterior wall of the uterus were found. Cystoscopy revealed oedema of the bladder wall. Excision of the mass and omentum was performed. The surgical diagnosis of abdominal actinomycosis with appendiceal abscess formation was confirmed histologically. Pathologic examination also showed actinomycosis of the resected bladder dome. Antibiotics were given post operatively. Patient has remained well.

¹ Registrar, Department of Diagnostic Imaging, Tan Tock Seng Hospital Pte. Ltd.

² Senior Consultant, Department of Diagnostic Radiology, Toa Payoh Hospital Pte. Ltd.

Correspondence to : Dr. Y Y Sitoh, Department of Diagnostic Imaging, Tan Tock Seng Hospital Pte. Ltd., Moulmein Road, Singapore 308433.

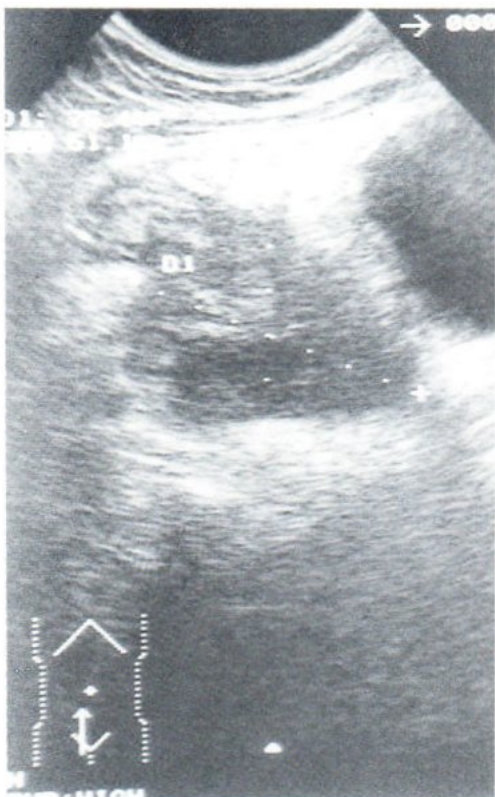

Fig. 1 Sagittal ultrasound shows a mixed echogenicity mass at the right iliac fossa, closely related to a loop of bowel superiorly.

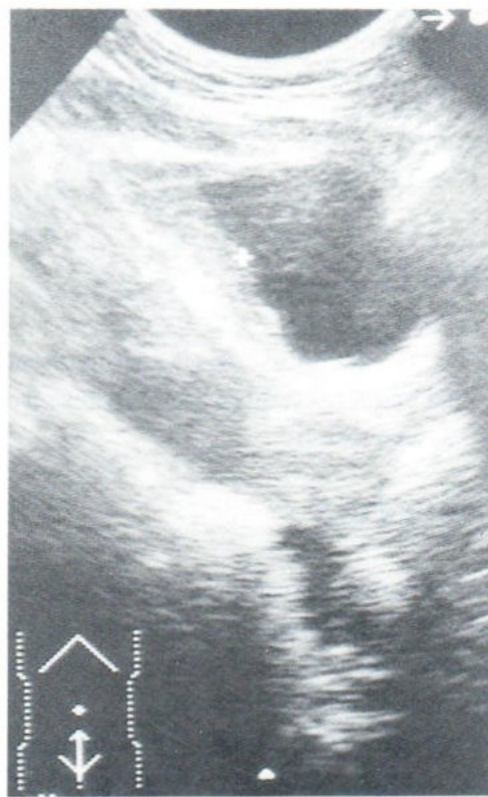

Fig. 2 Sagittal ultrasound shows a fixed undulating plaque at the bladder dome.

DISCUSSION

Actinomycosis is a chronic, progressive, suppurative and granulomatous infection. Sulphur granules characterise the colonies formed by this gram positive anaerobic or micro-aerophilic bacteria. The most common aetiologic agent, *Actinomyces israelii*, is a common saprophyte in the oropharynx and gastro-intestinal tract but appears unable to penetrate healthy mucosa. Opportunistic infection can occur with underlying local disease, trauma, surgery or the presence of foreign body.

Abdominal actinomycosis originates from the gastro-intestinal tract, especially the ilio-caecal region.^{1,2,7,8} There is a strong association with appendicitis and subsequent appendiceal rupture.^{4,9} It may present with multiple abscesses, draining sinuses, granulation and dense fibrosis. The production of proteolytic enzymes enables direct extension across dif-

ferent tissue planes.¹⁰ This pattern of spread and the tumour-like masses from fibrosis¹¹ imitate neoplastic disease.

CT of abdominal actinomycosis will often show infiltrative enhancing soft tissue masses with foci of decreased attenuation. Cystic masses with enhancing thick walls may also be seen.^{4,12} Lymphadenopathy is not a typical feature.¹² Urinary tract involvement is rare. Ultrasound may reveal hydronephrosis consequent to ureteric obstruction by the inflammatory mass.¹³ Demonstration of actinomycotic plaque-like bladder wall thickening, as shown in our patient, is distinctly uncommon.

Our case illustrates the difficulties in arriving at a correct diagnosis of actinomycosis. The presentation is often non-specific and the correct diagnosis made only at laparotomy. Though rare, it should be considered in the differential diagnosis in the proper clinical setting.

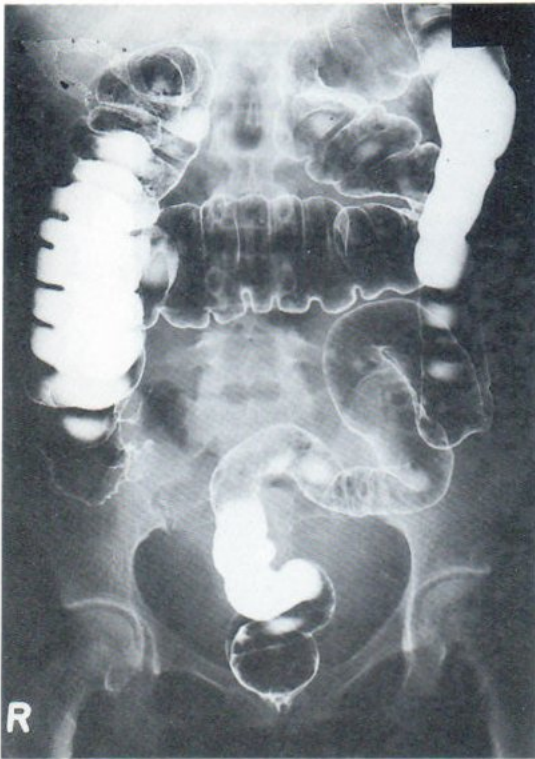

Fig. 3 Barium enema AP radiograph. Extrinsic lesion at the caecal pole distorts the outline. The rest of the colon is normal.

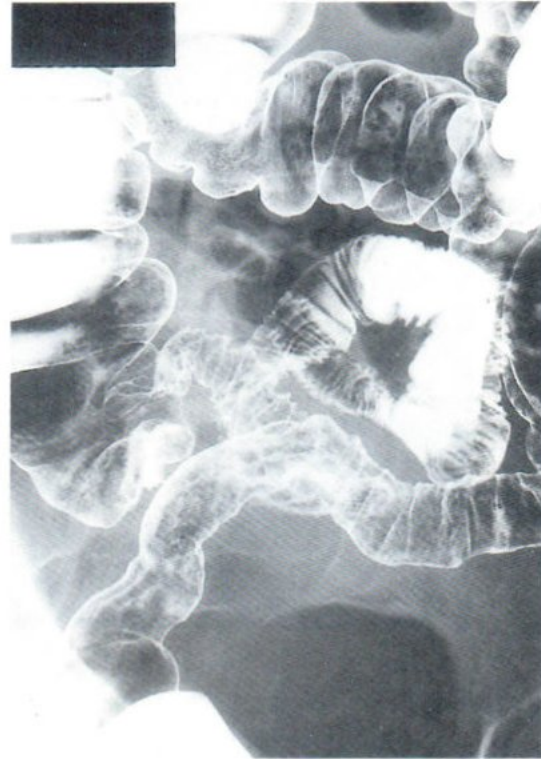

Fig. 4 Close up view of the ileo-caecal region. The caecal pole is persistently distorted with thickened, serrated terminal ileal folds.

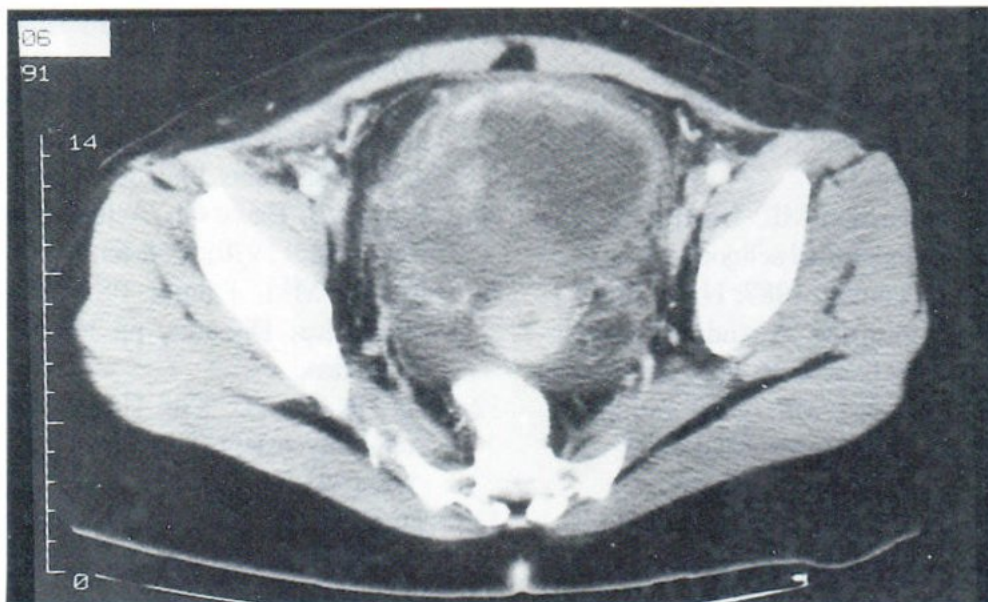


Fig. 5 Post contrast scan shows infiltration of the bladder dome. There is loss of the normal fat plane between the bladder and uterus. Free fluid is present.

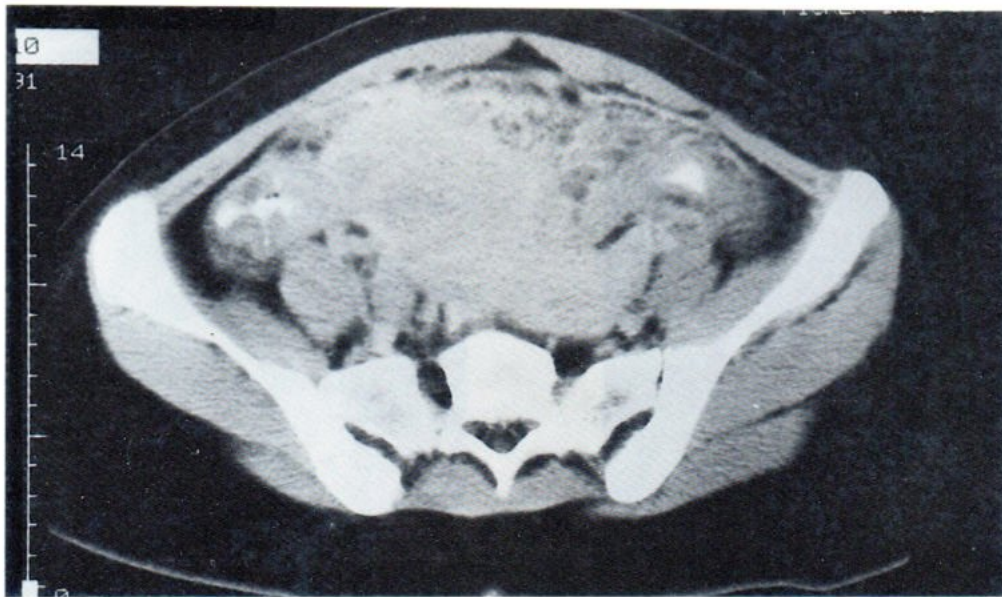


Fig. 6 Post contrast scan shows an enhancing infiltrative mass involving bowel and the anterior uterus. The bowel wall is thickened.

REFERENCES

1. Cope VZ. Visceral actinomycosis. *Br Med J* 1949; 2: 1311-6.
2. Davies M, Keddie NC. Abdominal actinomycosis. *Br J Surg* 1973; 60:18-22.
3. Webb WR, Sagel SS. Actinomycosis involving the chest wall: CT findings. *AJR* 1982; 139:1007-9.
4. Shah HR, Williamson MR, Boyd CM et al. CT findings in abdominal actinomycosis. *J Comput Assist Tomogr* 1987; 11(3): 466-9.
5. Weese WC, Smith IM. A study of 57 cases of actinomycosis over a 36 year period. A diagnostic "failure" with good prognosis after treatment. *Arch Intern Med* 1975; 135: 1562-8.
6. Harris LA, DeCosse JJ, Dannenberg A. Abdominal actinomycosis: evaluation by computed tomography. *Am J Gastroenterol* 1989 84: 198-200.
7. Fowler RC, Simpkins KC. Abdominal actinomycosis: a report of three cases. *Clin Rad* 1983;34: 301-7.
8. Deshmukh N, Heaney SJ. Actinomycosis at multiple colonic sites. *Am J Gastroenterol* 1986;81: 1212-4.
9. Wyngaarden JB, Smith LH. *Cecil's Text book of Medicine*, 18th edn., vol. 2, pp.1673-4. W.B. Saunders, Philadelphia.
10. Schwarz J, Baum GL. Actinomycosis. *Semin Roentgenol* 1970; 5: 58-63.
11. Reeder MM, Palmer PS. *The Radiology of Tropical Diseases*, pp 348-51. Williams & Wilkins.
12. Ha HK, Lee HJ, Kim H et al. Abdominal Actinomycosis: CT findings in 10 patients. *AJR* 1993; 161(4): 791-4.
13. Turnbull AE, Cohen MEL. Case report: pelvic actinomycosis with the development and resolution of a recto-sigmoid structure. *Clin Rad* 1991;43: 420-2.