

Classic Case:

Thymoma with pleural metastasis

Anutida Limsuknirun, M.D.

From The Department of Radiology,

Faculty of Medicine, Prince of Songkla University, Songkhla, Thailand

Address correspondence to A.L. (e-mail: anutida.limsuknirun@gmail.com)

Case summary

A previously healthy 46-year-old male presented with right-sided pleuritic chest pain for 2 weeks. He had no other symptoms such as febrile, cough, hemoptysis or dyspnea. He had no underlying disease and no history of cancer in his family. He reported no smoking and no alcohol drinking.

On physical examination revealed normal heart and lung sounds. His vital signs showed body temperature of 36.6°C, blood pressure of 128/83 mmHg, pulse rate of 90/minute, respiratory rate of 24/minute and 98% oxygen saturation.

Laboratory tests showed normal hemoglobin level, normal renal function and unremarkable liver function. White blood cell count was normal.

Chest radiography and enhanced chest computerized tomography (CT) scan showed a large pleural-based mass in the right side of the chest.

The patient underwent pleural biopsy via transthoracic needle biopsy (TTNB) on 11 January, 2018. Pathological findings for pleural specimens were consistent with thymoma.

Bone scan was done on 16 January, 2018 showing no evidence of bone metastasis.

Imaging findings

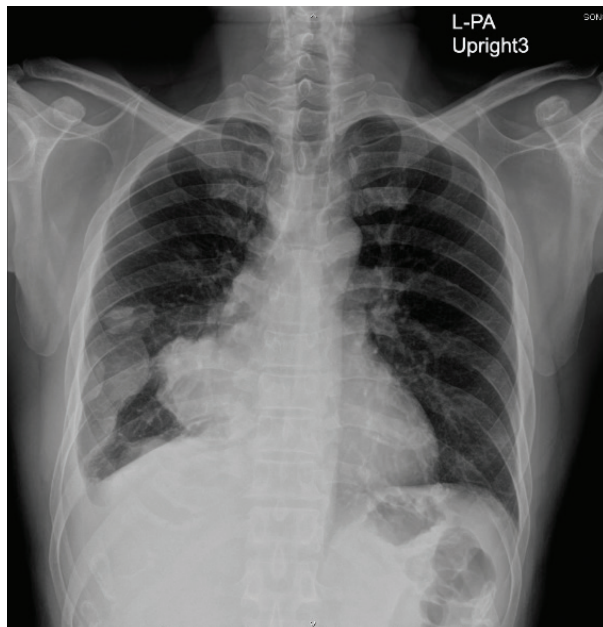

Figure 1. The initial chest radiograph reveals an anterior mediastinal mass and an adjacent pleural mass in the lower part of the right hemithorax.

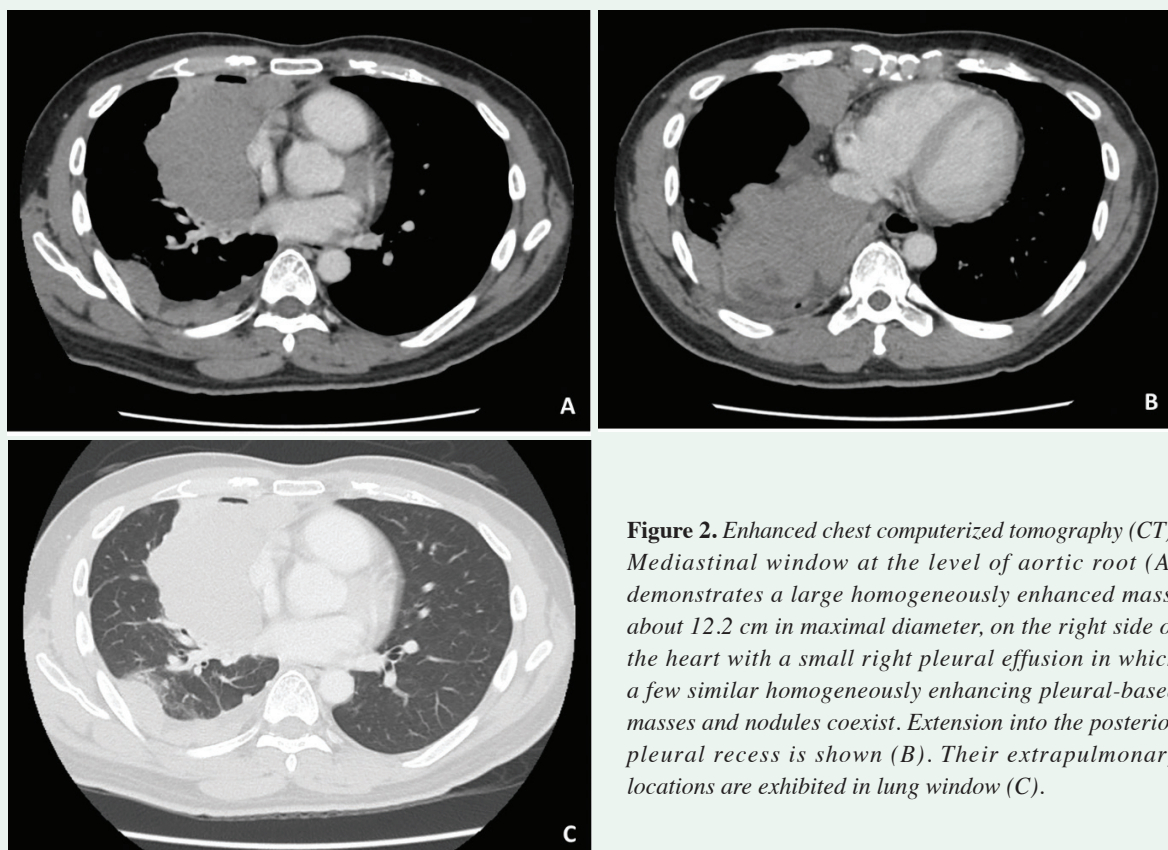


Figure 2. Enhanced chest computerized tomography (CT). Mediastinal window at the level of aortic root (A) demonstrates a large homogeneously enhanced mass, about 12.2 cm in maximal diameter, on the right side of the heart with a small right pleural effusion in which a few similar homogeneously enhancing pleural-based masses and nodules coexist. Extension into the posterior pleural recess is shown (B). Their extrapulmonary locations are exhibited in lung window (C).

Diagnosis

Thymoma with pleural metastasis

Discussion

Thymoma is a rare mediastinal neoplasm; however, it is the most common primary neoplasm of the thymus and anterior mediastinum.[8,14] It has an excellent prognosis for early stages and appropriately treated advanced stages.

Epidemiologic, Pathologic, and Clinical Features

Thymic neoplasms constitute less than 1% of all adult malignancies.[16] Thymomas typically occur in patients older than 40 years of age, usually present at the age of 50-60; also, they affect men and women equally.[8,14] They are slow-growing tumors that may show aggressive behaviors, such as invasion of adjacent structures and involvement of the pleura and pericardium. Nevertheless, lymphogenous and hematogenous metastases are uncommon.[6,9] They can develop myasthenia gravis and red cell aplasia, about 30%-50% and 50% of the patients, respectively.[11,15] They may also be associated with connective tissue disease, for instance, systemic lupus erythematosus and rheumatoid arthritis. In addition, Lymphoma, lung or thyroid carcinoma is sometimes related with thymomas (almost 20%).[11]

Most patients with thymoma are asymptomatic, so the tumor is incidental finding from chest radiography or CT scan. If symptoms present, they are usually associated with local effects of the neoplasm, including compression and invasion of adjacent structures, for example, dysphagia, diaphragm paralysis, or superior vena cava syndrome. Systemic complaints and paraneoplastic syndromes are classically due to hormones, antibodies, or cytokines secretion by the tumor.[6]

Staging

The most universally staging systems for thymoma recommended by the International Thymic Malignancy Interest Group (ITMIG) is the Masaoka-Koga staging.[3] It is based on the gross and microscopic properties of the neoplasm. Stage I is considered by complete encapsulation; stage II, by microscopic invasion through the capsule (IIa) or macroscopic invasion into surrounding fat (IIb); stage III, by invasion into an adjacent organ, such as the pericardium, great vessels, or lung; and stage IV, by pleural or pericardial spreading (IVa) or lymphatic-hematogenous metastasis (IVb).[4,6]

Thymoma Treatment Options according to the Masaoka-Koga Staging System [1-2,6]

Stage	Treatment
I	Complete surgical resection
II	Complete surgical resection; if resection is incomplete, postoperative radiation therapy
III	Neoadjuvant chemotherapy followed by complete surgical resection;* if resection is incomplete, postoperative radiation therapy
IVa	Neoadjuvant chemotherapy followed by complete surgical resection;* if resection is incomplete, postoperative radiation therapy
IVb	Palliative chemotherapy

**For stage III or IVa tumors, adjuvant chemotherapy may be considered, but data are insufficient to routinely recommend its use after complete resection.*

Imaging Evaluation

The role of imaging is for early diagnosis and suitably staging of thymoma, especially detection of local invasion and distant spreading, to identify candidates for preoperative neoadjuvant therapy, for instance, those with stage III or IV disease. Chest radiography is usually invisible normal thymus in adults; nevertheless, CT scan and MR imaging can visualize a triangular-shape of thymus especially at the level of aortic arch.[10,16]

CT scan is modality of choice of imaging to evaluate thymoma and may discriminate thymoma from other anterior mediastinal abnormalities. The character about extensive mediastinal lymphadenopathy, pleural effusions, and pulmonary metastases is usually more encountered in other neoplastic processes (eg, thymic carcinoma or lung cancer) than thymoma. Thymomas vary in sizes, typically ranging between 1 and 10 cm (mean, 5 cm) with smooth or lobulated shapes that characteristically arise from one lobe of the thymus. However, bilateral mediastinal involvement can also occur.[6,12] Most thymomas enhance homogeneously. About one-third of thymomas, nonetheless, can be seen heterogeneous enhancement due to necrosis, cystic change, or hemorrhage. Calcification may occur and can be punctate, linear along the capsule, or coarse and within the tumor.[6,12]

Thymomas sometimes cause vascular invasion, pleural involvement, or pericardial distribution. Direct signs of vascular involvement include an irregular vessel lumen contour, vascular encasement or obliteration, and endoluminal soft tissue, which may spread into cardiac chambers.[6,12] The CT study reveals one or more pleural nodules or masses with smooth, nodular, or diffuse characteristic which represent pleural dissemination or drop metastases. They are almost always ipsilateral to the anterior mediastinal tumor. Pleural effusion is unusual, even in the manifestation of widespread pleural metastases.[6-7]

At MR imaging, thymomas manifest with low to intermediate signal intensity on T1-weighted images, and with high signal intensity on T2-weighted images that may approach fat signal.[5-6,11] Fat-suppression techniques may be beneficial in distinguishing surrounding fat from thymoma. If thymoma has necrosis, hemorrhage or cystic change, MR imaging will show heterogeneous signal intensity. In addition, cystic changes and intratumoral necrosis manifest with low signal intensity on T1 weighted images and high signal intensity on T2 weighted images. According to the age of hemorrhage may appears to vary. Because of hemosiderin deposition, low signal intensity on T1- and T2 weighted images may be seen. Although CT is better than MR imaging in the representation of calcification within thymomas, MR imaging can occasionally reveal fibrous septa within the mass, as well as permit superior evaluation of the tumor capsule. Visualization of the capsule and of septa within a tumor has been shown to be associated with a less aggressive histologic appearance.[6,13]

Differential Diagnosis

The differential diagnosis for anterior mediastinal tumors includes other primary thymic malignancies (eg, thymic carcinoma, thymic carcinoid tumor), nonthymic tumors (eg, lymphoma, germ cell tumor, small-cell lung cancer), and mediastinal metastasis.[6] Age and gender of the patient, tissue structure as assessed at CT, additional CT findings, and evidence of invasion tumor are useful in increasing the differential diagnosis for anterior mediastinal masses.

Recurrence and Follow-up

Thymoma requires a prolonged follow-up. It is often important to detect recurrence initially, although complete resection can be succeeded. In doing so, results similar to those of patients without tumor recurrence after initial resection are achieved, with 65% to 80% ranging in 5-year survival rates.[10,16] Follow-up approvals of ITMIG advise that, chest CT should be done at least yearly for 5 years after surgical resection, and then alternated with annual chest radiography until year 11, followed by chest radiography once a year alone[3], since late recurrences are not unusual. Patients with resected stage III or IVa thymoma, thymic carcinoma, incomplete resection, or other high-risk tumors should undergo CT every 6 months for 3 years. While the use of MR imaging can benefit limit radiation dose, its facility to assist to identify early recurrence compared with CT has not been assessed.[6]

This case is classic because the most common anterior mediastinal tumor in adults is thymoma. The age at presentation is also typical. In addition, this case showed characteristic CT appearances which were homogeneously enhanced solid masses in the mediastinum with ipsilateral pleural spreading.

References

1. Falkson CB, Bezjak A, Darling G, Gregg R, Malthaner R, Maziak DE, et al. The management of thymoma: a systematic review and practice guideline. *J Thorac Oncol* 2009;4:911-9.
2. Girard N, Mornex F, Van Houtte P, Cordier JF, van Schil P. Thymoma: a focus on current therapeutic management. *J Thorac Oncol* 2009;4:119-26.
3. Huang J, Detterbeck FC, Wang Z, Loehrer PJ Sr. Standard outcome measures for thymic malignancies. *J Thorac Oncol* 2010;5:2017-23.
4. Koga K, Matsuno Y, Noguchi M, Mukai K, Asamura H, Goya T, et al. A review of 79 thymomas: modification of staging system and reappraisal of conventional division into invasive and non-invasive thymoma. *Pathol Int* 1994;44:359-67.
5. Maher MM, Shepard JA. Imaging of thymoma. *Semin Thorac Cardiovasc Surg* 2005; 17:12-9.
6. Benveniste MF, Rosado-de-Christenson ML, Sabloff BS, Moran CA, Swisher SG, Marom EM. Role of imaging in the diagnosis, staging, and treatment of thymoma. *Radiographics* 2011;31:1847-61; discussion 1861-3.
7. Moran CA, Travis WD, Rosado-de-Christenson M, Koss MN, Rosai J. Thymomas presenting as pleural tumors. Report of eight cases. *Am J Surg Pathol* 1992;16:138-44.
8. Morgenthaler TI, Brown LR, Colby TV, Harper CM Jr, Coles DT. Thymoma. *Mayo Clin Proc* 1993;68:1110-23.
9. Regnard JF, Magdeleinat P, Dromer C, Dulmet E, de Montpreville V, Levi JF, et al. Prognostic factors and long-term results after thymoma resection: a series of 307 patients. *J Thorac Cardiovasc Surg* 1996;112:376-84.
10. Regnard JF, Zinzindohoue F, Magdeleinat P, Guibert L, Spaggiari L, Levasseur P. Results of re-resection for recurrent thymomas. *Ann Thorac Surg* 1997;64:1593-8.
11. Restrepo CS, Pandit M, Rojas IC, Villamil MA, Gordillo H, Lemos D, et al. Imaging findings of expansile lesions of the thymus. *Curr Probl Diagn Radiol* 2005;34:22-34.
12. Rosado-de-Christenson ML, Strollo DC, Marom EM. Imaging of thymic epithelial neoplasms. *Hematol Oncol Clin North Am* 2008;22:409-31.
13. Sadohara J, Fujimoto K, Müller NL, Kato S, Takamori S, Ohkuma K, et al. Thymic epithelial tumors: comparison of CT and MR imaging findings of low-risk thymomas, high-risk thymomas, and thymic carcinomas. *Eur J Radiol* 2006;60:70-9.
14. Santana L, Givica A, Camacho C; Armed Forces Institute of Pathology. Best cases from the AFIP: thymoma. *Radiographics* 2002;22 Spec No:S95-S102.
15. Strollo DC, Rosado de Christenson ML, Jett JR. Primary mediastinal tumors. Part 1: tumors of the anterior mediastinum. *Chest* 1997;112:511-22.
16. Ströbel P, Bauer A, Puppe B, Kraushaar T, Krein A, Toyka K, et al. Tumor recurrence and survival in patients treated for thymomas and thymic squamous cell carcinomas: a retrospective analysis. *J Clin Oncol* 2004;22:1501-9.