

TRANSCATHETER GLUE EMBOLIZATION IN A CASE OF POST-TRAUMATIC PSEUDOANEURYSM AND AV FISTULA OF THE RENAL ARTERY

Jiemjit TAPANEEYAKORN M.D., Chamaree CHUAPETCHARASOPON M.D.
Sirintara PONGPECH M.D., Chatchai THANUDUMRONG M.D.

ABSTRACT

Transcatheter glue embolization in a case of a large post stabwound pseudoaneurysm and AV fistula of left renal artery was presented. The patient was 18-year-old man who had left flank pain and hematuria. The process of treatment was simple, cheap, effective and safe. The kidney and its function could be preserved.

INTRODUCTION

The reported incidence of pseudoaneurysm and AV fistula was considered rare, it occurred only about 0.01%-6.25%.¹ The main encountered causes are iatrogenic, usually following needle biopsy or percutaneous catheterization¹ and other traumatic events. The incidence of renal artery aneurysms is 0.01%-1%² and it accounts for 22% of all visceral aneurysms.³

Usually renal artery aneurysms are treated surgically.³ Various percutaneous embolization techniques have also been performed with success.⁴ Therapeutic embolization of the renal artery has been used to control bleeding, devascularize tumors, close AV fistula, obliterate aneurysms, control hypertension and infarct kidneys in an end-stage renal disease.

We report the treatment of a case of renal artery pseudoaneurysm and AV fistula, using the transcatheter glue embolization.

CASE REPORT

An 18-year-old Thai male had a stab wound injury at left flank for 1 week with left flank

pain and hematuria. No excretion was observed from left kidney at IVP (Fig.1) and the contrast medium was seen only at the cortical part of left kidney and an enhanced tubular structure in the central part of left kidney from the images of the first CT scan (Fig.2). Retrograde pyelography showed an old blood clot at left ureteric orifice and left ureteric obstruction at mid ureter. Doppler ultrasonography and arterial phase ultrafast CT scan of the kidneys showed an AV fistula with a large false aneurysm, about 4 cm in diameter of the intrarenal branch of left renal artery (Fig.3-5). Left renal angiography confirmed this diagnosis (Fig.6).

The left renal fistula and aneurysm was embolized using a total of 1 cc. of glue (Histoacryl) with good success. The first 0.5 cc of glue was injected through a 3-F microcatheter which was introduced via the original 5-F Cobra catheter, while the tip of the catheter was placed in the feeding artery and the tip of the microcatheter was placed in the aneurysm. After the first embolization and the microcatheter was removed, the fistula was still seen whereas the aneurysm was smaller. Then, the second 0.5 cc of glue was

injected via the same Cobra catheter, while the tip of the catheter was placed in the left renal artery, just proximal to the fistula.

Selective left renal angiography with a new Cobra catheter after the second embolization showed the disappearance of the aneurysm and

fistula. Minimal nephrogram at the lateral aspect of the middle pole kidney was lost due to ischemia which was an accepted finding (Fig.7).

Follow up CT scan 2 weeks later showed only small renal infarction but the renal function and the creatinine level was normal (Fig.8). The hematuria also disappeared after the embolization.

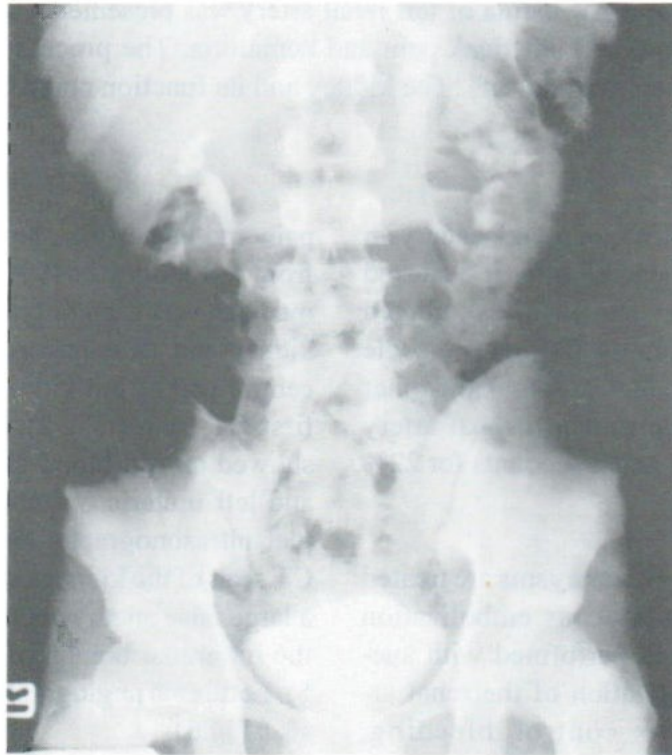


Fig. 1. No excretory function was seen from left kidney with an IVP study.

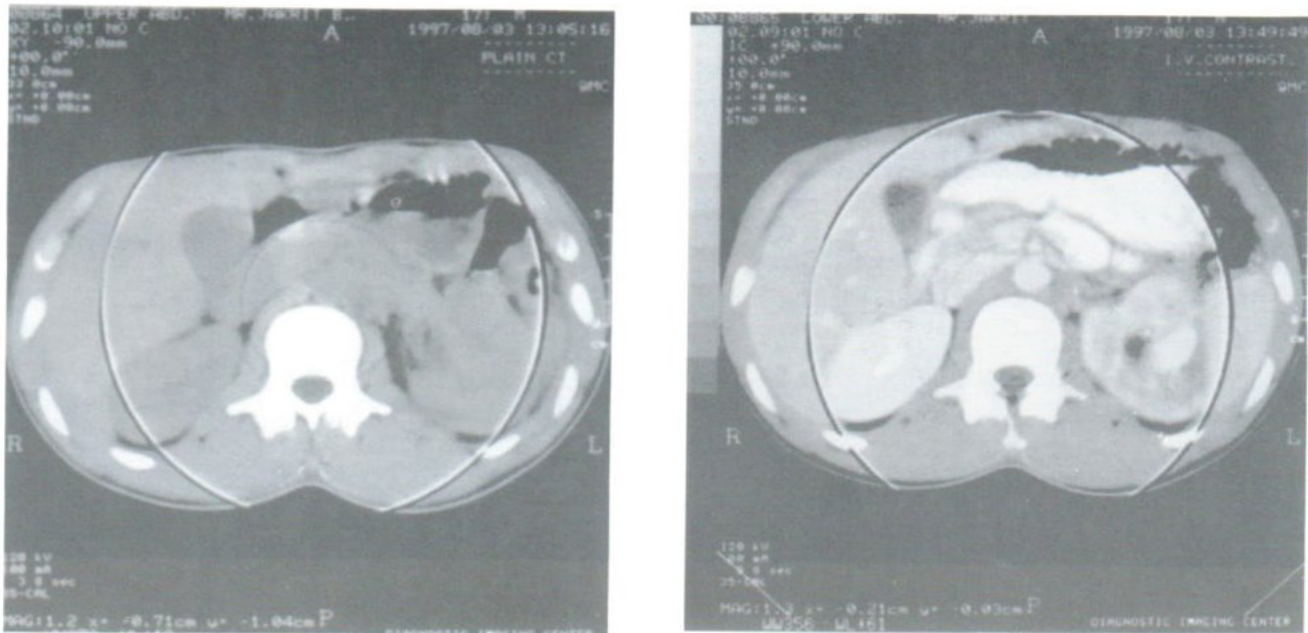


Fig. 2. AT CT scan, the excreted contrast medium was seen only at the cortical part of left kidney. An enhanced tubular structure was noted in the central part of left kidney.

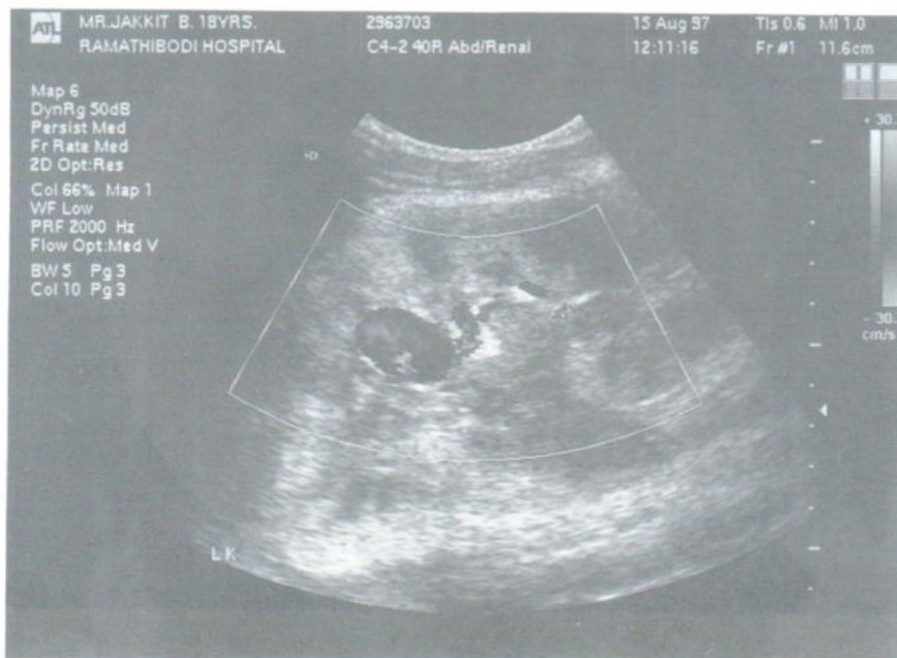

Fig. 3. Doppler ultrasonography showed an AV fistula and large intrarenal pseudoaneurysm.

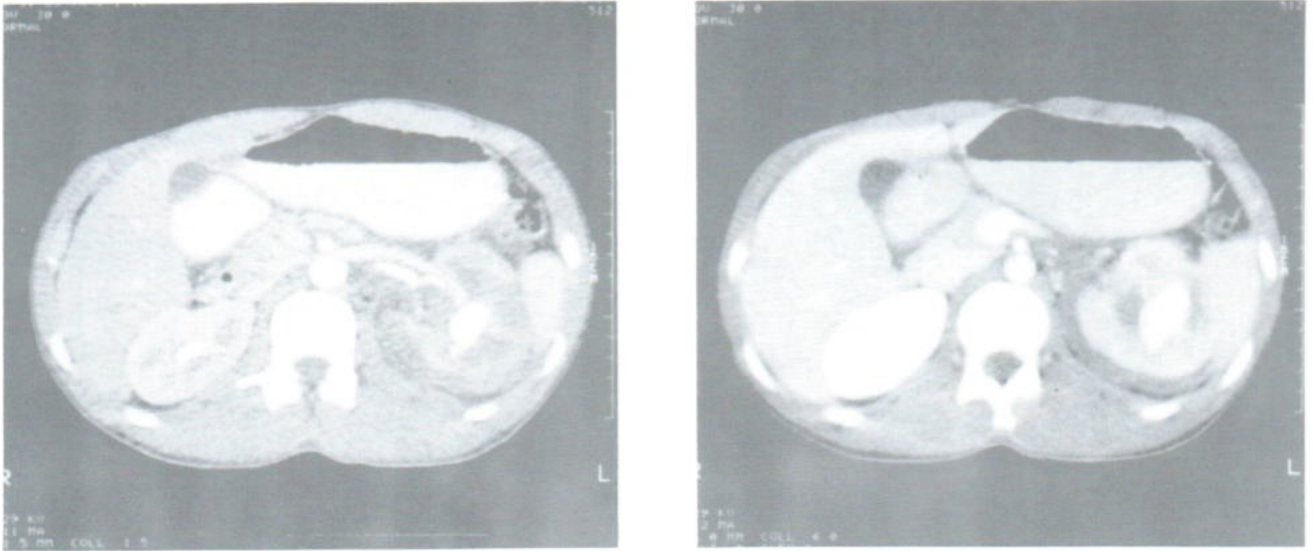


Fig. 4,5. Early and late arterial phase ultrafast CT scan of the kidney showed a large pseudoaneurysm with an early draining vein, representing an AV fistula.

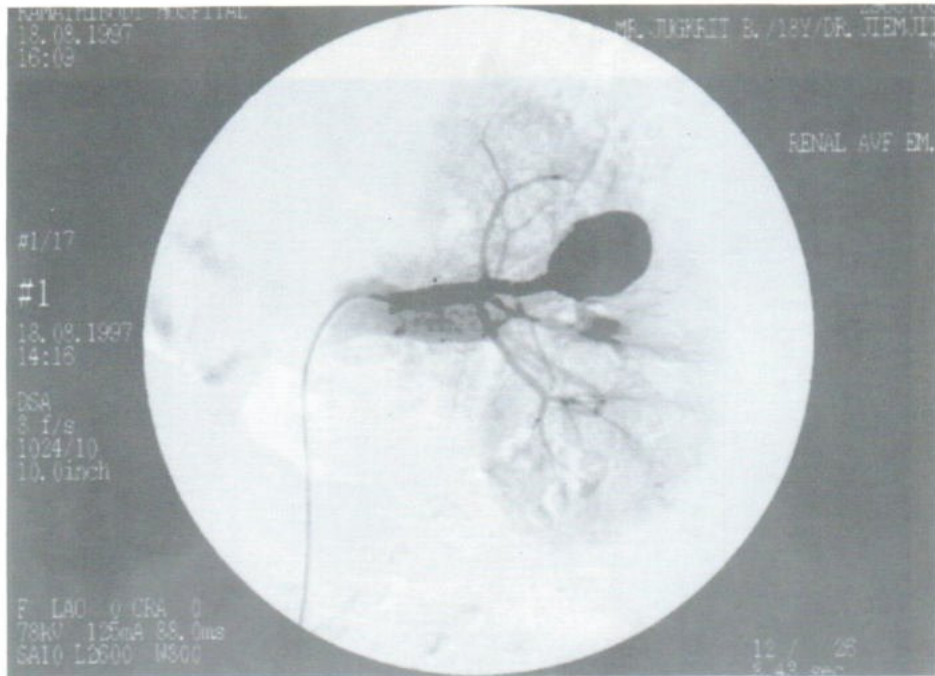


Fig. 6. Renal angiogram showed an early draining vein, representing AV fistula. Some turbulent flow within the large pseudoaneurysm was observed.

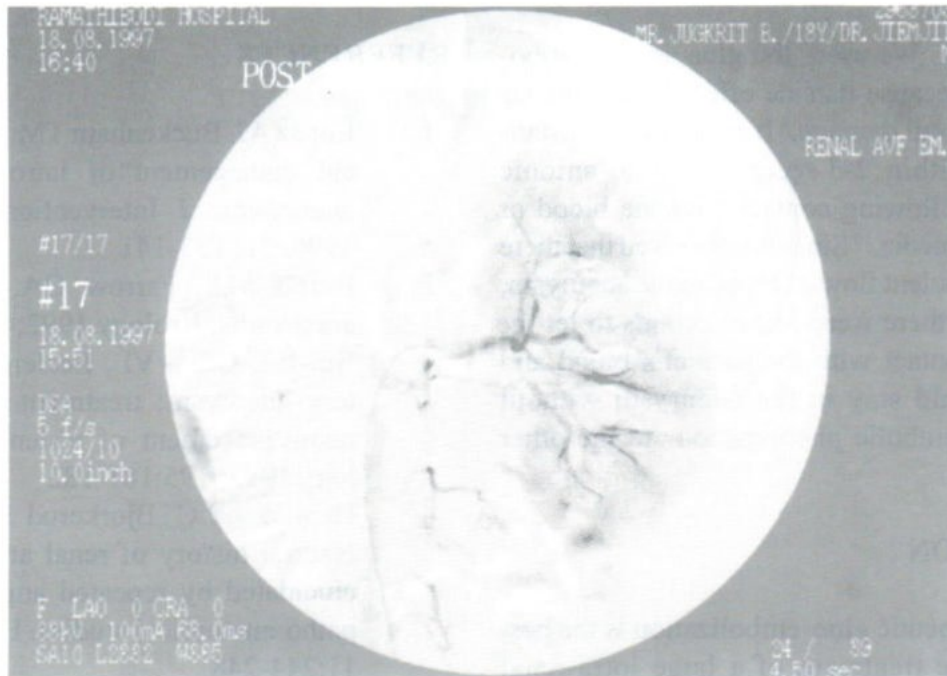


Fig. 7. Left renal angiogram immediately post embolization showed disappearance of the pseudoaneurysm and the fistula and ischemia of middle pole of left kidney.

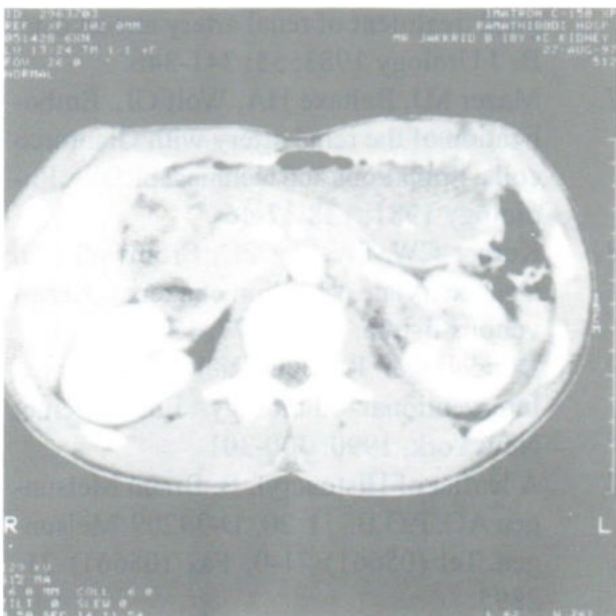


Fig. 8. Follow up CT scan two weeks later showed the disappearance of both fistula and the pseudoaneurysm; good excretory function of left kidney was observed.

DISCUSSION

The indications for the treatment of the renal artery aneurysms include pain, hypertension, hematuria, large aneurysm and pregnancy.⁵ Aneurysms that are greater than 1 centimeter in diameter (calcified or not) should be treated surgically.^{6,7} The involved urologist had the opinion that surgical treatment could not save the involved kidney in our case.

The Gianturco steel coils with or without gelfoam, has become particularly popular and effective in occluding the main renal artery.² The pseudoaneurysm in this case was too large to use the coils, because more than five coils were probably needed and its cost would be about 12,500 Bahts. One cc. of the glue costs only 492 Bahts.

The active principle of the glue is Enbucrilate which is known as a tissue adhesive agent and is classified as an investigational device by the United states food and drug

administration. We used the glue as a thrombogenic agent because its side effect is thrombosis and vascular wall damage.⁹ It polymerizes instantaneously (within 2-3 seconds) by an anionic mechanism following contact with the blood or other ionized media.¹⁰ Since we observed that there was some turbulent flow of blood in the aneurysm, it meant that there were some seconds to let the glue make contact with the patient's blood and polymerize and stay in the aneurysm without causing any embolic phenomenon to the other vessels.

CONCLUSION

Therapeutic glue embolization is the best option for the treatment of a large intra-renal pseudoaneurysm and AV fistula, to preserve renal parenchyma and the renal function.⁸ High quality digital subtraction arteriography (DSA) with a rapid frame rate and multiple oblique projections is desirable prior to any attempts to embolization. The size of the parent vessel, and the communication between the parent artery and the aneurysmal sac must be accurately defined before the treatment.

ACKNOWLEDGMENTS

We would like to extend our thanks to Rames Watcharasin M.D., and Vithya Varavithya M.D. for scanning images, Bussanee Wibulprasert M.D. for doppler examination and Krisada Ratana-Olarn M.D., the urologist in charge.

REFERENCES

1. Lopez AJ, Buckenham TM. The radiological management of iatrogenic pseudoaneurysms. *J Interventional Radiology* 1996; 11: 133-141
2. Bulbul MA, Farrow GA. Renal artery aneurysms. *Urology* 1992;40:124-126
3. Bui BT, Oliva VL, Leclere G. Renal artery aneurysm: treatment with percutaneous placement of a stent graft. *Radio-logy* 1995; 195:181-182
4. Henriksson C, Bjorkerud S, Nilson AE. Natural history of renal artery aneurysm elucidated by repeated angiography and patho-anatomical studies. *Eur Urol* 1985; 11:244-248
5. Glass PM. Aneurysms of the renal artery: a study of 20 cases. *J Urology* 1967; 98: 285-292
6. Ortenberg J, Norick AC, Stretten RA. Surgical treatment of renal artery aneurysms. *Br J Urology* 1983; 55: 341-346
7. Mazer MJ, Baltaxe HA, Wolf GL. Embolization of the renal artery with Gianturco coils: limitations and technical pitfalls. *Radiology* 1981; 138:37-46
8. Kerber CW, Freency PC, Cromwell LD. Cyanoacrylate occlusion of a renal arteriovenous fistula. *AJR* 1977; 128: 663
9. Dondelinger RF, Kurdziel JC, Rossi R. *Interventional Radiology*. Ed. Thieme; New York, 1990: 300-301
10. A leaflet of Histoacryl. B. Braun Melsungen AG. P.O.B. 11 20, D-34209 Melsungen. Tel (05661) 71-0, Fax (05661) 71-2895