

## CT SCAN OF INTRACRANIAL AIR EMBOLISM: POST CARDIOPULMONARY RESUSCITATION

Anannit VISUDTIBHAN<sup>1</sup>, Patchrin PEKANAN<sup>2</sup>, Sirintara PONGPECH<sup>2</sup>,  
Suphaneewan JAOVISIDTH<sup>2</sup>, Klaus W PREIDLER<sup>3</sup>

### ABSTRACT

A case report of intracranial intravascular air detected by CT scan was performed. The images obtained immediately after the patient expired post failed cardiopulmonary resuscitation in an 11-year-old child who had unknown cause of hepatitis.

### INTRODUCTION

Cerebral air embolism has been previously reported in many situations including trauma to the head,<sup>1</sup> cardiothorax<sup>2</sup> and to the cervical spine. Caisson's disease,<sup>3</sup> operations in neurosurgery, in gynecology<sup>4</sup> and in cardiothorax<sup>5</sup> can introduce air to the intracranium. Pneumothorax, percutaneous lung biopsy, lung cancer, arterial or venous catheterization,<sup>6</sup> mechanical positive pressure ventilation,<sup>7</sup> esophagoatrial fistula,<sup>8</sup> intra-aortic balloon pumping catheter insertion,<sup>9</sup> angiography,<sup>10</sup> hemodilution<sup>13</sup> and intravenous transfusion has also been reported as causes of cerebral air embolism.

A pediatric case of massive cerebral arterial and venous air embolism detected by CT scan immediately post cardiopulmonary resuscitation is presented.

### CASE REPORT

An 11-year-old girl was admitted for liver biopsy and a detailed investigation due to unknown cause of hepatitis. Physical examination revealed a mildly pale and alert girl with icteric sclera, palmar erythema, hepatosplenomegaly and eczema at both legs. The liver biopsy was deferred because of the prolonged coagulogram. The hospital

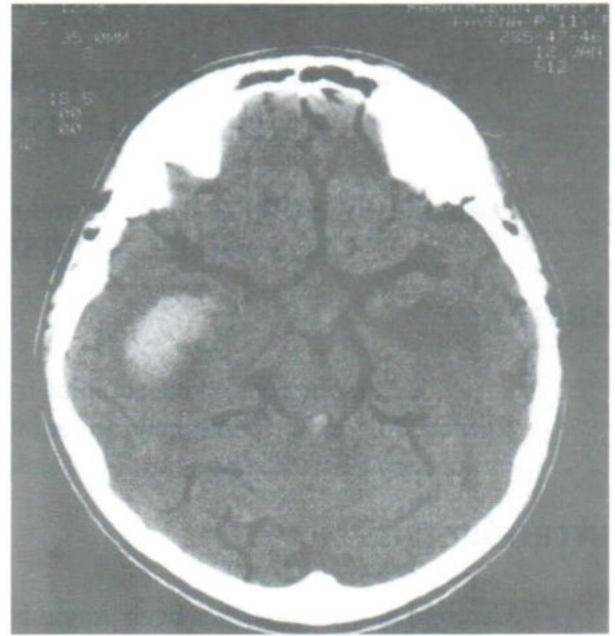
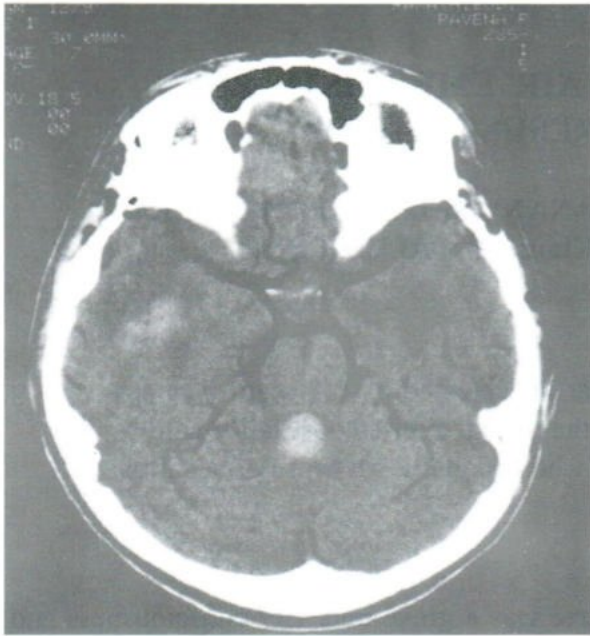
course was a grave one. Her consciousness and renal function was deteriorated in a short period of time and she has also fever. No clinical improvement was observed after peritoneal dialysis, antibiotics, intravenous immunoglobulin and D. penicillamine administration. Later she had respiratory distress, hypotensive, fixed dilated right pupil which was not reactive to light. The patient developed cardiac arrest on the way to the CT room. CT scan was performed; however, despite failed cardiopulmonary resuscitation.

Nonenhanced axial CT scan of the brain revealed extensive low density of air in both arteries and veins intracranially. Air was observed in both carotid and vertebrobasilar systems (Fig.1). Both areas of cavernous sinuses were filled with air (Fig.2). Less air was detected in the dural venous sinuses (Fig.3). In addition, a large hematoma was shown in right cerebral hemisphere which extended to the ventricular system. Air was also observed in the anterior part of the intracerebral hematoma (this air should come from the artery which was ruptured) (Fig. 4). Air in the intraorbital vasculature was also seen. No air was detected from plain chest film.

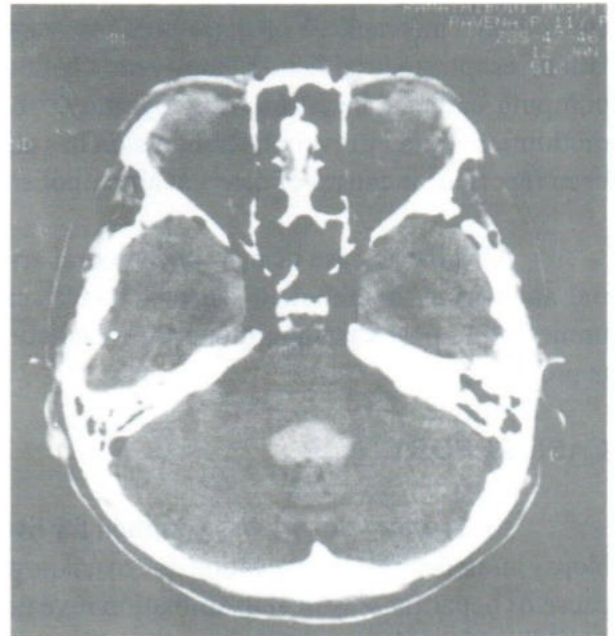
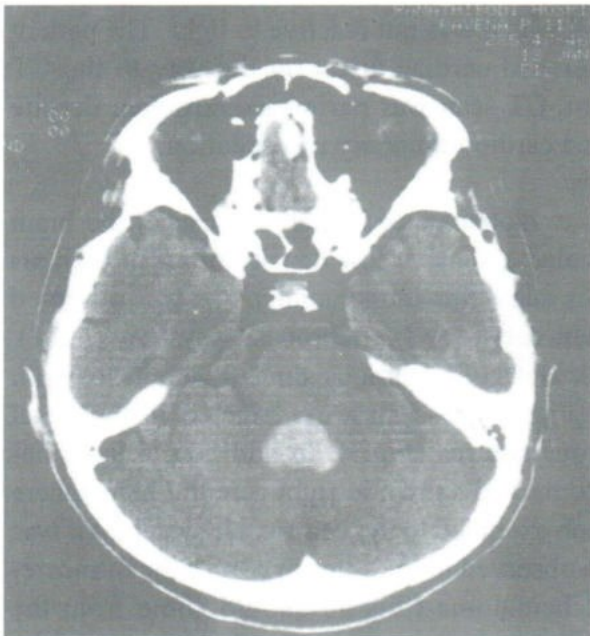
<sup>1</sup> Department of Pediatrics, Ramathibodi Hospital, Rama 6 Street, Bangkok 10400, Thailand

<sup>2</sup> Department of Radiology, Ramathibodi Hospital

<sup>3</sup> Department of Radiology, Karl Franzens university Graz, Graz, Austria

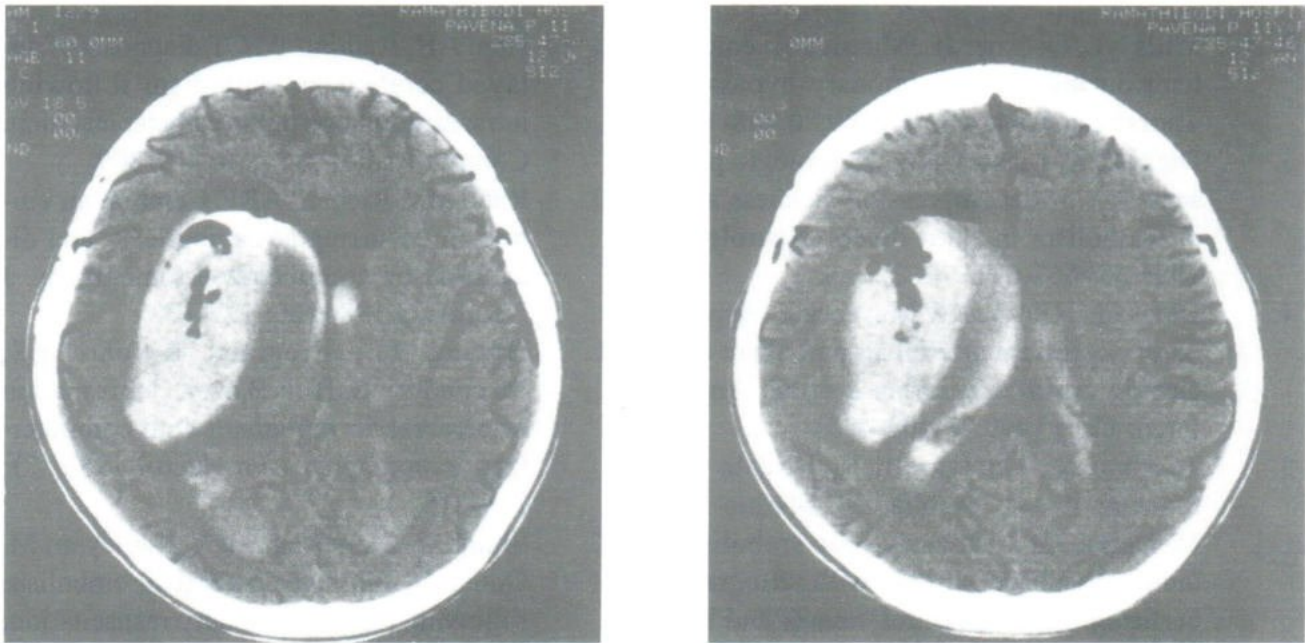


**Fig. 1.** NCE CT scan of the brain showed air in the arteries of carotid and vertebrobasilar system of both sides, (hematoma is also noted in right temporal lobe, and in the 4<sup>th</sup> ventricle)



**Fig. 2.** NCE axial CT scan of the brain showed air in the cavernous sinuses. (The hematoma in the 4<sup>th</sup> ventricle is observed.)

**Fig. 3.** NCE CT scan of the brain showed less air in the right sigmoid sinus (The hematoma in the 4<sup>th</sup> ventricle).



**Fig. 4.** NCE axial CT scan of the brain showed a large right cerebral hemispheric hematoma, leaking to lateral ventricle. Note the air in the hematoma, probably came from the ruptured artery. (Air in the convexity arteries of both sides were also shown.)

NCE = Non - contrast enhanced.

## DISCUSSION

Systemic air embolism is almost invariably iatrogenic except for cases of penetrating trauma to the thorax, lungs, major vessels or in decompression sickness.<sup>11</sup> Shiina et al<sup>12</sup> reported two cases of massive cerebral arterial air embolism associated with posttraumatic cardiopulmonary resuscitation. It was proposed that mechanical impact of cardiopulmonary resuscitation resulted in pulmonary barotrauma and pushed massive air into the arterial circulation and the intracerebral arteries.

The mechanism whereby venous air is transferred to the arterial circulation is controversial.<sup>13</sup> Air is able to pass through an existing intracardiac septal defect into the systemic circulation if there is increase in right heart pressure from pulmonary outflow obstruction.<sup>14</sup> Paradoxical

cerebral air embolism could occur without intracardiac septal defects.<sup>15</sup> Certain conditions may allow the passage of venous air to the systemic circulation through the pulmonary arteriovenous barrier.<sup>16</sup>

Detection of air is thought to be dependent on the timing of the CT scan and on the amount of air which initially entered the vessels to the brain; the earlier the initial scan and the greater the quantity of air, the more likely it is to be detected.

## REFERENCES

1. Butler BD, Hills BA. Transpulmonary passage of venous air emboli. *J Appl Physiol* 1985; 59: 543-547

2. Mills NL, Ochsner JL. Massive air embolism during cardiopulmonary bypass. *J Thorac Cardiovasc Surg* 1980;80:708-717
3. Dick APK, Massey SW. Neurologic presentation of decompression sickness and air embolism in sport divers. *Neurology* 1985;35: 667-671
4. Davis FM, Glover PW, Maycock E. Hyperbaric oxygen for arterial air embolism occurring during Caesarian section. *Anest Intens Care* 1990;18:403-405
5. Toscano M, Chiavarelli R, Ruvolo G, Machiarelli A, Serblia G, Marino B. Management of massive air embolism during openheart surgery with retrograde perfusion of the cerebral vessels and hyperbaric oxygenation. *Thorac Cardiovasc Surg* 1983; 31: 183-184
6. Kearns PJ, Han IK AA, McDonald TW. Homonymous hemianopia due to cerebral air embolism from cerebral venous catheter. *West J Med* 1984; 40:615-617
7. Michael AM, Milton LP, Ronald BP. Detection of pneumoencephaly secondary to mechanical ventilation in neonates. *J Comput tomogr* 1981; 5: 328-332
8. Nadjimi M, Schaffer R, Wordartz R. Cerebral arterial air embolism due to an esophago-atrial fistula seen on CT. *Neuroradiology* 1979;18:103-106
9. Hani AH, Ayming W. CT diagnosis of delayed cerebral air embolism following intraaortic balloon pump catheter insertion. *Comput Radiol* 1987;10: 307-309
10. Rand MV, Richard ARF. Cerebral air embolism occurring at angiography and diagnosed by computerized tomography. *J Neurosurg* 1984; 60: 177-178
11. Hwang TL, Fremaux R, Sears ES, MacFadyen B, Hills B, et al. Confirmation of cerebral air embolism with computerized tomography. *Ann Neurol* 1983; 13: 214-215
12. Shiina G, Shimosegawa Y, Kameyam M, Onuma T. Massive cerebral air embolism following cardiopulmonary resuscitation. Report of two cases. *Acta Neurochir (Wien)* 1993; 125: 181-183
13. Hirabuki N, Miura T, Mitomo M, et al. Changes of cerebral air embolism shown by computed tomography. *The British Journal of Radiology* 1988;61: 252-255
14. Ponsky JL, Pories WJ. Paradoxical cerebral air embolism (Letter). *New England Journal of Medicine* 1971; 284: 985
15. Kearns PJ, Haulk AA, McDonald TW. Homonymous hemianopia due to cerebral air embolism from central venous catheters. *Western Journal of Medicine* 1984; 140: 615-617
16. Butlers BD, Hills BA. The lung as a filter for microbubbles. *Journal of Applied Physiology* 1979; 47: 537-543