

---

## CLINICAL EVALUATION OF TECHNETIUM-99M LABELLED HUMAN POLYCLONAL IMMUNOGLOBULIN G FOR MUSCULOSKELETAL INFECTION

Chanika SRITARA<sup>1</sup>, Opas SINPHURMSUKSKUL<sup>2</sup>, Vipa BOONKITTICHAROEN<sup>1</sup>, Pornchai MULPRUK<sup>2</sup>, Rojana SIRISRIRO<sup>1</sup>, Payap CHOKESUWATTANASKUL<sup>1</sup>, Daungpen PUCHINDA<sup>1</sup>, Anna Ngonrath Na AYUDHYA<sup>1</sup>, Putthiporn CHOUPLYWECH<sup>1</sup>, Puangtong KRIPHIBUL<sup>1</sup>.

### ABSTRACT

**BACKGROUND:** Three-phase bone scan is highly sensitive in detecting infection of the musculoskeleton. However, its low specificity necessitates the search for a more definite measure. This study was designed to determine the sensitivity and the specificity of <sup>99m</sup>Tc-labelled polyclonal human IgG (HIG) for the detection of infection of the musculoskeleton and to compare these to that of conventional three-phase bone scintigraphy.

**METHODS:** Thirty-four patients with suspected infection of the musculoskeleton underwent <sup>99m</sup>Tc-labelled polyclonal human IgG (HIG) scintigraphy 48 hours after 3-phase bone scintigraphy. Both scans were graded on a five-point scale by visual interpretation. The final diagnosis was established by means of bacteriologic culture, histopathologic analysis of surgical specimen or clinical follow-up (follow-up time of 28 ± 13 months). There were 44 sites evaluated. Receiver operating characteristic (ROC) curve analysis was generated for both modalities.

**RESULTS:** At their optimal threshold levels (score 3) of the HIG scan, the sensitivity, specificity, accuracy, likelihood ratios and area under the ROC curve were 84.61%, 96.77%, 93.18%, 26.23, and 0.967, respectively, while those of the 3-phase bone scan were 100%, 87.10%, 90.70%, 7.75, and 0.941, respectively. No adverse reaction was encountered.

### INTRODUCTION

Infection of the musculoskeleton often presents a diagnostic and therapeutic problem, making the management of the disease difficult. This issue is troublesome in cases with post-traumatic, chronic infection, or those underwent surgical intervention. Its diagnosis may be aided by infection imaging.

Bone scintigraphy has been used for many years for the investigation of infection of the skeleton. Although the sensitivity of bone scan is close to 100% in chronic osteomyelitis, but specificity is low.<sup>1</sup> This justifies the use of additional techniques.

---

<sup>1</sup> Division of Radiotherapy and Nuclear Medicine, Department of Radiology,

<sup>2</sup> Department of Orthopaedics, Faculty of Medicine, Ramathibodi Hospital, Rama VI Road, Bangkok 10400, Thailand



$^{67}\text{Ga}$ -citrate is more specific than bone scanning, but false-positives may occur in conditions such as healing fractures and noninfected prostheses.<sup>2,3</sup> Besides, it must be imported for each patient and be used within a certain period, otherwise it will decay away. Moreover, it is rather expensive in comparison to  $^{99\text{m}}\text{Tc}$ , the most commonly used radionuclide in nuclear medicine.

Labelled-leukocytes do not accumulate at sites of increased bone-mineral turnover in the absence of infection and would seem to be an ideal radiotracer for infection. The sensitivity and specificity range from 66%-95% and from 35%-100%, respectively.<sup>4,5,6,7</sup> Furthermore, the labelling process is laborious, it requires a flow hood and other expensive equipment not readily available; and cells can become damaged during the labelling process if care is not taken.<sup>8</sup> There may be possibilities of contaminating and mis-administering the blood.<sup>9</sup>

Radiolabelled monoclonal antigranulocyte antibodies and polyclonal human IgG have been recently introduced as radiotracers for infection imaging. Although no serious adverse reaction had been reported, when comparing radiolabelled polyclonal human IgG with monoclonal antigranulocyte antibodies, there is a problem of the mouse origin of the latter agent, thus possibly inducing HAMA with its risk for allergic reactions, altered biodistribution after repeated injection.<sup>10</sup> Like labelled leukocytes, radiolabelled monoclonal antigranulocyte antibodies have physiological uptake in bone marrow, making axial osteomyelitis almost impossible to diagnose with confidence.<sup>11</sup> Furthermore, marrow occasionally turns up in the distal extremities<sup>12</sup> so the addition of bone marrow imaging with  $^{99\text{m}}\text{Tc}$ -sulphur colloid is required to improve specificity.<sup>13</sup>

Polyclonal human IgG is attractive in that it is available in kit form; the tedious labelling

technique of leukocytes can be avoided; the chance of contamination is minimised; no expensive equipment is required; and there will be no HAMA (Human anti-mouse antibody) reaction. This study was designed to determine the sensitivity and the specificity of  $^{99\text{m}}\text{Tc}$ -labelled polyclonal human IgG (HIG) for the detection of infection of the musculoskeleton and to compare these to that of conventional three-phase bone scintigraphy.

## MATERIALS AND METHODS

### PATIENTS

During October 1994-September 1996, 36 patients suspected of having musculoskeletal infection agreed to join this study were included. Informed consent were obtained from all patients. There were 16 patients with hip prosthesis and 19 patients without. Written informed consent was obtained from all patients. Two patients were loss to follow-up so we were left with 34 patients (21 females and 13 males), age ranged from 17-71 years (mean  $\pm$  SD =  $48 \pm 19$ ). In the patients with prosthesis, 4 patients had bilateral hip prostheses yielding 19 prostheses for assessment. The interval from replacement ranged from 1-216 months (mean  $\pm$  SD =  $45.11 \pm 10.95$ ). In those without prosthesis, there were 25 sites being suspected for infection. There were altogether 44 sites evaluated.

### SCINTIGRAPHY

The protocol was approved by the hospital ethical committee. All of the patients, except one who underwent a HIG scan only, underwent three-phase bone scan and, 48 hours later, HIG scan. Images were acquired with an Elscint Helix dual head gamma camera using a high-resolution, parallel-hole collimator. Imaging parameters were 140 keV photopeak, 20% window and 128x128 matrix. Both examinations were performed in supine position; anterior and posterior images of



the hips or sites of interest were obtained.

Whenever possible, SPECT and 24-hour static images were also acquired with the same gamma camera and collimators. The SPECT acquisition was obtained into 128x128 matrices, 6 degree and 25 seconds per step for 60 steps using body contour orbit. The SPECT images were back-projected and filtered with a Hanning filter (a power of 2 and a cut-off frequency of 2).

### THREE-PHASE BONE SCAN

Three-phase bone scan was performed in each patient with 15 mCi of <sup>99m</sup>Tc-MDP. Anterior and posterior images of the hips or other sites of suspected infection were imaged. In the first phase, a set of 2-second images was acquired for 1 minute. For the second phase, static planar images of the same site were acquired for 1 minute. Three hours after injection, static images were acquired to signify osseous phase.

### <sup>99m</sup>Tc-LABELLED POLYCLONAL HUMAN IgG

Radiolabelling were performed according to Boonkitticharoen et al. Eighteen mCi of <sup>99m</sup>Tc-labelled polyclonal human IgG was administered slowly intravenously. Four hours afterwards images were obtained.

### INTERPRETATION

Both three-phase bone and HIG studies were separately evaluated by visual interpretation by a nuclear medicine physician blinded to the final diagnosis and the results of other imaging modalities. The visual findings were graded on a five-point scale of 0-4 according to table 1 and 2 for 3-phase bone scan and HIG scan, respectively. For each modality, sensitivity, specificity, accuracy, positive and negative predictive values were calculated at the optimal scaling threshold. A

receiver operating characteristic (ROC) curve was generated and the likelihood ratios at each scaling point were obtained.

Table 1. Descriptions of each grade of HIG scan findings

Table 2. Descriptions of each grade of Bone scan findings

### FINAL DIAGNOSIS

Final diagnosis of the 44 sites in 33 patients was assessed by surgery in 22 patients (23 sites), by blood culture in 1 patient (1 site), by aspiration culture in 3 patient (4 sites), by wound swab culture in 4 patients (4 sites), by follow-up in 12 patients (12 sites, median follow-up time of 24 months). The latter included four asymptomatic contralateral prostheses used as negative controls, which were followed 7 to 14 months.

### STATISTICAL ANALYSIS

Statistical analysis to show differences between both scintigraphic procedures was performed with a paired test according to Hanley and McNeil.<sup>14</sup> A p-value of <0.05 was considered statistically significant.

### RESULTS

According to the final diagnosis (Tables 1 and 2), of the 44 sites investigated, there were 13 infected sites. These included 7 sites of hip infection (3 with prostheses), 2 sites of osteomyelitis, 3 sites of cellulitis (1 accompanying osteomyelitis), and 1 site of tuberculous abscess. The diagnoses of all of the infected lesions were verified by obtaining positive cultures of surgical, aspiration, blood, or wound swab specimen. Of the 31 uninfected sites, the verification procedures were surgery in 16 sites, clinical follow-up in 12 cases (median follow-up time of 24 months).

wound swab culture in 2 cases, and aspiration culture in 1 case.

No adverse reaction to HIG was observed.

Table 3. Individual data for patients with suspected septic hip prosthesis.

Table 4. Individual data for patients with suspected musculoskeletal infection without hip prostheses.

The optimal threshold was chosen from the scaling level where highest accuracy was obtained in each scan. It appeared to be at level 3 for both scans (Table 1 and 2).

**Table 1** Description of each grade of HIG scan findings

Positive if Greater Than or Equal to	Increased Activity at Suspected Site
0	none
1	minimal
2	moderate but less than that of vessel
3	equal to that of vessel
4	greater than that of vessel

**Table 2** Description of each grade of Bone scan findings

Positive if Greater Than or Equal to	Increased Activity at Suspected Site			
	Soft tissue		Bone	
	Early	Delayed	Early	Delayed
0	none	none	none	none
1	none	mild	none	mild to intense
2	mild	none to moderate	mild	mild to intense
3	moderate	none to moderate	moderate	moderate to intense
4	intense	intense	intense	moderate to intense



With three-phase bone scintigraphy, perfect sensitivity and negative predictive value were obtained. No false negative result occurred. On the other hand, HIG scan dramatically had higher likelihood ratio and moderately increased specificity at the price of sensitivity. There were less false positive results, however, according to the ROC analysis, the accuracy of HIG was not significantly higher than 3-phase bone scintigraphy in the detection of musculoskeletal infection ( $p > 0.25$ ). With HIG scan, there was one false-positive result with a score of 4 (uptake greater than vascular activity) in a patient who turned out to have Ewing sarcoma. This was also one of the 4 false positive cases on 3-phase bone scan. The rest were due to old healed osteomyelitis in 2 case and post-traumatic changes in 1 case.

Table 5. The results, sensitivity, specificity, accuracy, positive predictive ratio, negative predictive ratio, likelihood ratio areas under ROC curves and standard errors of both scans

There was only one false positive result on HIG study, which was also false positive on 3-phase bone study, due to Ewing sarcoma. Three other false positive results with 3-phase bone studies were due to old healed osteomyelitis (patient 2 and 4 in table 4) and healing fracture

(patient 1 in table 3).

In those without prostheses (Table 4) patient 2 was presented with a history of on and off discharge from a wound on her right thigh for a few years. She had been put on courses of antibiotic therapy now and then. An active osteomyelitis involving the adjacent Rt. femoral shaft was suspected at the time of examination. Her plain films showed thickening of the adjacent cortical bone and her contrast sinugram showed no connection between the wound and the adjacent bone. The 3-phase bone scan revealed increased activity at the Rt. femoral shaft on both early and delayed images. The HIG study showed focal abnormality of grade 3 (more intense than femoral vein) confining to the lateral aspect of the thigh, suggesting the location of soft tissue rather than bone. Intra-operatively, the bone was sclerotic. There was no evidence to suggest active process of osteomyelitis and the bone culture was negative, while the infection of the soft tissue was verified by a culture from the sinus tract. The increased activity in bone on both early and delayed images can be seen in active remodelling process and does not necessarily signify bone infection. In this case HIG seemed to localise the site of infection more accurately than bone scan.

**Table 3.** Individual data of patients with suspected musculoskeletal infection with hip prostheses.

Pt	Sex	Age (yrs)	Site of prosthesis	Score		Diagnosis and clinical findings	Verification procedure	Culture	Final Dx		Result	
				Bone	HIG				Bone HIG		Bone HIG	
1	F	54	R	3	0	Healing fx femoral shaft & loosening stem and cup	Sx	NG	NI	FP	TN	
2	F	59	R	1	1	No evidence of infection	Sx	NG	NI	TN	TN	
			L	1	0	Asymptomatic	FU (14m)	-	NI	TN	TN	
3	M	43	R	0	0	Loosening, not infected	Sx	-	NI	TN	TN	
			L	1	0	Asymptomatic	FU (12m)	-	NI	TN	TN	
4	F	63	L	1	0	Loosening stem and cup no evidence of infection	Sx	NG	NI	TN	TN	
5	F	70	L	2	0	Decreased pain on conservative	FU (6m)	-	NI	TN	TN	
6	M	66	R	0	0	Sx: mild softening of cancellous bone at greater trochanter patho: nondiagnostic	Sx	-	NI	TN	TN	
7	F	74	R	4	4	Septic prosthetic hip	Sx	MRSA	I	TP	TP	
8	F	41	L	1	0	Severe metallosis, erosion of shaft screw, not loosening	Sx	-	NI	TN	TN	
9	F	67	R	4	4	Rt. hip pain with fever 2d improved with ATB Rx	blood	Strep.	I	TP	TP	
10	M	63	R	4	4	Septic prosthetic hip	Sx	Strep.D	I	TP	TP	
11	M	42	L	1	0	Protrusion of prosthetic head	FU (24m)	-	NI	TN	TN	
12	F	67	R	1	0	Sx: no evidence of infection	Sx	NG	NI	TN	TN	
			L	1	0	Asymptomatic	FU (7m)	-	NI	TN	TN	
13	F	70	R	1	0	Sx: loosening, not infected	Sx	NG	NI	TN	TN	
			L	1	0	Asymptomatic	FU (7m)		NI	TN	TN	
14	M	60	L	1	0	Improved after conservative Rx	FU (24m)		NI	TN	TN	
15	F	44	L	1	0	Dysplastic with flexion contracture	aspiration	NG	NI	TN	TN	

ATB = antibiotics; Bone = bone scintigraphy; d = days; Dx = diagnosis; F = female; FU = follow-up; fx = fracture; HIG = HIG scintigraphy; I = infected; L = left; m = months; M = male; MRSA = methicillin resistant Staphylococcus aureus; NG = no growth; NI = not infected; Pt. = patient; R = right; Rx = treatment; Strep. = Streptococci; Strep. D = Streptococci group D; Sx = surgery; TN = true negative; TP = true positive; yrs = years



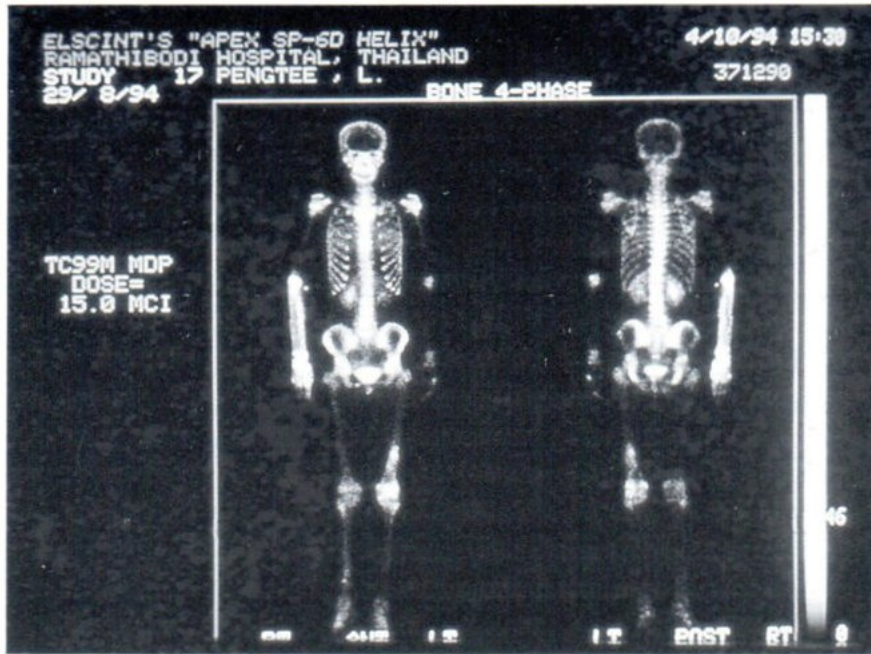
**Table 4.** Individual data of patients with suspected septic hip prosthesis

Pt	e	S	Age (yrs)	Site	Score on HIG	Diagnosis and clinical findings	Verification procedure	Culture	Final Dx	Result	
										Bone	HIG
1	F	44	Lt. hip	nd	3	Septic hip	Sx	SCN	I	nd	TP
2	F	17	Lt. femoral shaft	3	0	No OM	Sx	NG	NI	FP	TN
			Adjacent soft tissue	3	4	Cellulitis	wound swab	SA	I	TP	TP
3	M	26	Rt. hip	3	3	Septic hip	aspiration	S	I	TP	TP
4	M	37	Rt. fibial shaft	3	1	No OM	Sx	NG	NI	FP	TN
			Adjacent soft tissue	3	3	Cellulitis	wound swab	PA	I	TP	TP
5	M	17	Rt. femoral shaft	4	3	OM	Sx	SA	I	TP	TP
6	F	23	Lt. ischeopubic ramus	4	4	Ewing sarcoma	Sx	-	NI	FP	FP
7	F	53	Rt. hip	4	4	Bilateral septic hips	aspiration	MRSA	I	TP	TP
			Lt. hip	4	4		aspiration	MRSA	I	TP	TP
8	M	41	Rt. femoral shaft	4	4	COM	Sx	SA	I	TP	TP
			Adjacent soft tissue	3	2	Cellulitis	Sx	SA	I	TP	FN
9	M	19	Rt. hip	2	2	Old neglected comminuted fx	Sx	NG	NI	TN	TN
10	F	35	Lt. hip	2	2	SLE with bilateral AVN	Sx	NG	NI	TN	TN
			Rt. hip	2	0		FU (45m)	-	NI	TN	TN
11	F	25	Sacrum	0	0	Ulcer at sacral region	wound swab	NG	NG	NI	TN
12	F	71	Rt. hip	0	0	Bursitis improved with NSAID	FU (29m)	-	NI	TN	TN
13	F	31	Lt. hip	0	0	Hip pain, normal CT&MRI Not worsening on FU	FU (36m)	-	NI	TN	TN
14	F	58	Rt. hip	2	2	Hip pain S/P removal of prosthesis	Sx	NG	NI	TN	TN
15	M	31	Rt. hip	1	0	Arthritis secondary from AVN	Sx	NG	NI	TN	TN
16	M	35	Sacrum	0	0	Not involved	FU (10m)		NI	TN	TN
			Rt. Buttock	3	3	Tuberculous abscess	Sx	MTB	I	TP	TP
17	M	77	Low back	0	0	Ulcer at low back	wound swab	NG	NI	TN	TN
18	F	39	Lt. hip	2	2	Chronic hypertrophic synovitis	Sx	NG	NI	TN	TN
19	F	70	Lt. hip	0	1	Arthritis	FU (29m)	-	NI	TN	TN

AVN = avascular necrosis; cart. = cartilage; COM = chronic osteomyelitis; d/c = discharge; FU = follow-up; fx = fracture; I = infected; L = left; m = months; MRSA = methicillin resistant Staphaphylococcus aureus; MTB = M. tuberculosis; ND = not done; NG = nogrowth; NI = not infected; OM = osteomyelitis; PA = Pseudomonas aeruginosa; R = right; Rx = therapy S = Salmonella; SA = Staphylococcus aureus; SCN = Staphylococcus coagulase negative; Sx = surgery

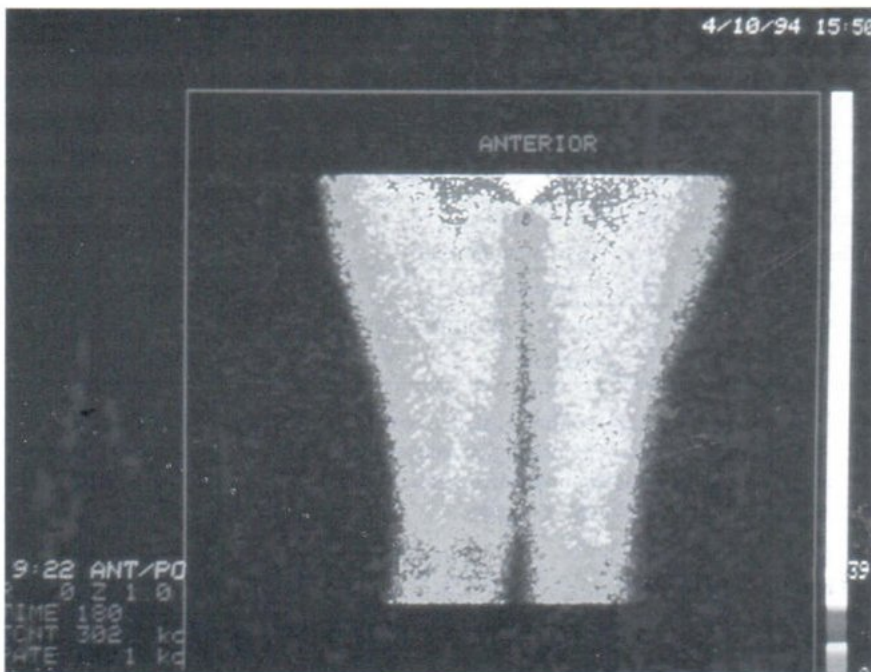
**Table 5** Summary of results of both scans

Study	TP	FP	TN	FN	Total	Sensitivity	Specificity	Accuracy	P(+)	P(-)	Likelihood	Area under
											Ratio	ROC curve
<b>HIG</b>	12	1	30	1	44	92.31	96.77	95.45	92.31	96.77	28.61	0.971 (0.025)
<b>Bone</b>	12	4	27	0	43	100	87.1	90.7	75	100	7.75	0.957 (0.029)



1A

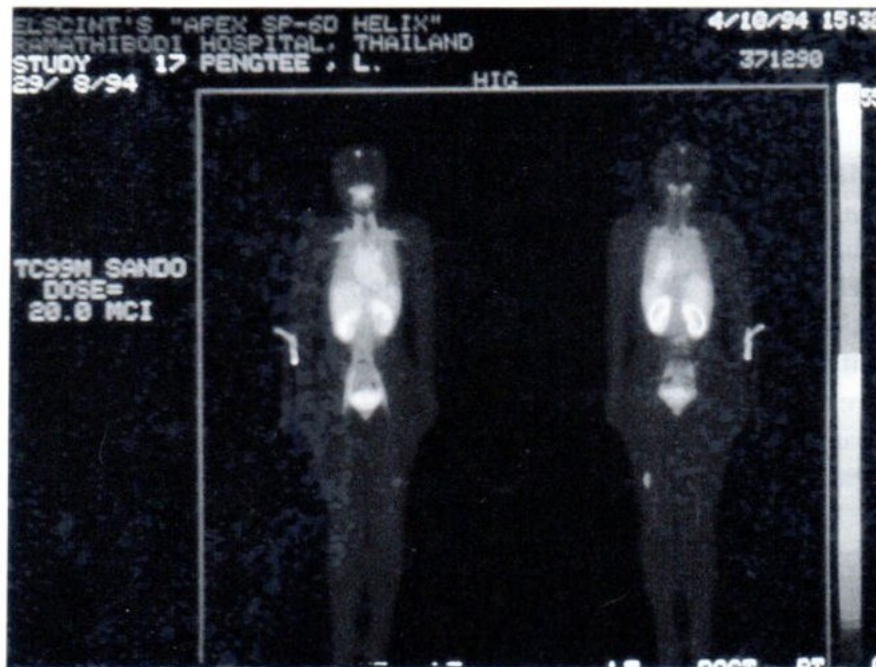**Fig. 1** Patient 2 from table 4 with on and off discharge from her right thigh had been treated now and then with antibiotics for 2 years. The clinical question was whether there was active osteomyelitis at the time. Three-phase bone scan revealed increased activity at the right femoral shaft on delayed images (A) and increased soft tissue activity around that region on early images (B)



1B

**Fig. 1 (B).** Increased soft tissue activity around femoral shaft region on early images.





1C

**Fig. 1 (C)** HIG scan (C) showed focally increased activity at the lateral aspect of the right thigh, the intensity of which was higher than that of the femoral vein.

## DISCUSSION

The bone and its surrounding soft tissue were assessed separately on both studies in an attempt to differentiate mere cellulitis from cellulitis with osteomyelitis as their management differs. Clear differentiation between the two was possible only when the soft tissue involvement lied or extended laterally away from the normal osseous locations. In smaller parts of the body, such as hands and feet, this may not be possible. However, there was no such case in our study. This was also a problem with  $^{99m}\text{Tc}$  labelled monoclonal antigranulocyte antibody-immunoscintigraphy.<sup>15</sup> Whether SPECT is of value in this setting needs further study to confirm.

In most cases, the intensity of HIG uptake corresponded to the probability of infection. However, the only one false positive case, due to Ewing sarcoma, had most intense uptake. This was likely to be due to increased vascularity in these condi-

tions since it is one of the probable mechanisms of localisation of HIG. Reported conditions causing false positive results with specific and non-specific immunoglobulin are hematoma, recent fracture, pseudarthrosis, osteonecrosis and tumours.<sup>16,17,18</sup>

The exact mechanism of localisation of HIG at the sites of infection is yet to be elucidated and various hypotheses have been suggested. These include binding of the Fc fragment of the immunoglobulin G to Fc receptors on inflammatory cells, binding to bacteria and rheumatoid factors and increased vascular permeability.<sup>19</sup> As the mechanisms of localisation imply, the HIG study cannot differentiate sterile inflammation from bacterial infection. According to Pons et al<sup>20</sup> the HIG study is also an objective test to detect synovitis and to assess the severity of inflammation. They found that the intensity of  $^{99m}\text{Tc}$ -HIG



uptake correlated significantly with markers of inflammation in patients with rheumatoid arthritis. In our study it was clearly demonstrated that the intensity of uptake could not distinguish the nature of the lesions in terms of the presence of infection because both true infection and Ewing sarcoma took up HIG avidly. Demirkol et al<sup>21</sup> performed a quantitative analysis of <sup>99m</sup>Tc-HIG uptake to detect infection in hip and knee prostheses using target to background ratio and reported no significant difference between the true-positive and false-positive cases.

It was a pity that late HIG imaging at 24 hours was performed in only some cases in this study as it was reported that by which separation the infections from the noninfectious inflammations could be made rather well.<sup>22</sup> In that study a numerical value named the inflammation index was obtained by dividing the average counts per pixel in an area of interest circumscribing the musculoskeletal foci of accumulation, by the average counts per pixel in an equal size area drawing in an unaffected symmetrical site. Analysis of variance (ANOVA) showed that this index of late HIG study was able to differentiate infections and noninfectious inflammations ( $p = 0.016$ ). However, using the lower limit of 95% confidence interval of the study as a threshold for infection resulted in a sensitivity, specificity and accuracy of 78.57%, 50% and 64.29%, respectively. This may imply that even the performance of the late inflammation index of HIG, which was shown to work statically, was far from ideal practically. The inflammation index of HIG was increased or decreased in late imaging in comparison to its early counterpart in both infection and noninfectious inflammation. As a result this cannot differentiate these conditions.

Despite comparable sensitivity, the specificity in this study were higher than that in the work of Ang et al<sup>23</sup> (86% and 16%) and Demirkol et al<sup>21</sup> (100% and 41%). The apparently good

sensitivity, specificity, accuracy, positive predictive value and negative predictive value reported in our study might be partly due to limited sample size and limited number of patients with sterile arthritis. If there had been more patients, particularly those with inflammatory joint diseases, the number of false positive cases might have been higher and the specificity, accuracy, and negative predictive value might have been lower.

The high sensitivity of 3-phase bone scintigraphy in detecting the presence of musculoskeletal infection has been well recognised. However, because the specificity of bone scintigraphy is far from ideal, several radiopharmaceuticals have been investigated for this matter. Some recommended combined labelled leukocytes/marrow scintigraphy and some <sup>18</sup>F-FDG. Labelled leukocytes, be it with conventional technique or with monoclonal anti-granulocyte antibodies are feasible. However, the conventional technique needs blood handling, expensive instrument, and personnel expertise and is time consuming. Despite the fact that labelling with the latter eliminates all the disadvantages of the conventional technique, it is expensive and has a potential to develop HAMA upon repeated use. Moreover, labelled leukocytes are taken up at the bone marrow so in those with post-traumatic or surgical changes, the leukocyte may be misleading and the addition of a bone marrow scan may not always solve the problem.<sup>24</sup> <sup>18</sup>F-FDG PET has been reported to detect chronic osteomyelitis with high accuracy. Yet, it is of limited value in discriminating between inflammation and malignancy because tumour cells also show high FDG accumulation.<sup>25</sup> Moreover, it is not available in most part of the world, particularly in Thailand. To date, there is no commercially available radiopharmaceutical that can definitely differentiate infection from sterile inflammation. The only radiopharmaceutical claimed to be specific to bacterial infection was Infecton,<sup>26</sup> <sup>99m</sup>Tc labelled ciprofloxacin. However, it is not commercially available.



The HIG study appeared to have comparable sensitivity, specificity and accuracy to that of labelled leukocytes. It is available in a relatively low-priced kit form. Its preparation is easy and safe. The uptake in the bone marrow and HAMA reaction are absent. Considering all these, the HIG study appears it be a good alternative to labelled leukocytes and monoclonal antigranucyte antibodies for localising infection.

At 4 hours most of the  $^{99m}\text{Tc}$ -labelled polyclonal human IgG remained in the blood pool, therefore the heart, moderate-sized veins and highly vascular organs such as the spleen, liver and kidneys were seen. Excretion was noted in the urinary bladder. As a result the  $^{99m}\text{Tc}$ -labelled polyclonal human IgG may not be used to localise infection in these organs satisfactorily.

## CONCLUSION

A HIG study may be used as a screening test of the investigation of painful hip prosthesis and suspected musculoskeletal infection. If no increased activity is seen at the suspected site, it is very unlikely that infection is present. A HIG study appeared to be a safe and convenient method with reasonable sensitivity, specificity and accuracy for the detection of infection. However, differentiation between infection and sterile inflammation cannot be definitely made.

## ACKNOWLEDGEMENTS

This study was partly supported by WHO. The authors also would like to thank Dr. Mantana Dhanachai for her valuable comments on this study.

## REFERENCES

1. Tumech SS, Tohmeh AG. Nuclear medicine techniques in septic arthritis and osteomyelitis. *Rheum Dis Clin North Am* 1991;17:559-83.
2. Al-Sheikh W, Sfakianakis GN, Mnaymneh W, et al. Subacute and chronic bone infection: diagnosis using In-111, Ga-67 and Tc-99m MDP bone scintigraphy, and radiography. *Radiology* 1985;155:501-6.
3. Palestro CJ. The current role of gallium imaging in infection. *Semin Nucl Med* 1994;24:128-141.
4. Vorne M, Soini I, Lantto T, Paakinen S. Technetium-99m HMPAO-labelled leukocytes in detection of inflammatory lesions: comparison with gallium-67 citrate. *J Nucl Med* 1989; 30:1332-6.
5. El Esper I, Dacquet V, Paillard J, Bascoulergue G, Tahon MM, Fonroget J.  $^{99}\text{Tc}^m$ -HMPAO-labelled leucocyte scintigraphy in suspected chronic osteomyelitis related to an orthopedic device: clinical usefulness. *Nucl Med Comm* 1992;13: 799-805.
6. Weissman BN. Current topics in the radiology of joint replacement surgery. *Radiol Clin North Am* 1990;28:1111-34.
7. Wukich DK, Abreu SH, Callaghan JJ, et al. Diagnosis of infection by preoperative scintigraphy with indium-labelled white blood cells. *J Bone Joint Surg [Am]* 1987; 69:1353-60.
8. Datz FL, Taylor AT. Cell labelling: techniques and clinical utility. In: Freeman LM, ed. *Freeman & Johnson's clinical radionuclide imaging*, 3rd edition. Orlando: Grune & stratton 1984;1785-913.
9. Goodwin DA. New methods for localizing infection: a role for avidin-biotin? *J Nucl Med* 1992;33:1816-8.



10. Sakaha H, Reynolds JC, Carrasquillo JA, et al. In vitro complex formation and biodistribution of mouse antitumor monoclonal antibody in cancer patients. *J Nucl Med* 1989;30:1311-7.
11. Reske SN. Marrow scintigraphy. In: Murray IPC, Ell PJ, eds. *Nuclear medicine in clinical diagnosis and treatment*. Edinburgh: Churchill Livingstone, 1994: 705-9.
12. Peters AM. The choice of and appropriate agent for imaging inflammation. *Nucl Med Commun* 1996;17:455-8.
13. Palestro CJ, Torres MA. Radionuclide imaging in orthopedic infections. *Semin Nucl Med* 1997;4:334-5.
14. Hanley JA, McNeil BJ. A method of comparing the areas under receiver operating characteristic curves derived from the same cases. *Radiology* 1983;148: 839-43.
15. Kaim A, Maurer T, Ochsner P, Jundt G, Kirsch E, Mueller-Brand J. chronic complicated osteomyelitis of the appendicular skeleton: diagnosis with technetium-99m labelled monoclonal antigranulocyte antibody-immunoscintigraphy. *Eur J Nucl Med* 1997;24:732-8.
16. Seybold K, Locher JT, Coosemans C, Andres RY, Schubiger PA, Blauentein P. Immunoscintigraphic localization of inflammatory lesions: clinical experience. *Eur J Nucl Med* 1988;13:587-93.
17. Lind P, Langsteger W, Koltringer PK, Dimai HP, Passl R, Eber O. Immunoscintigraphy of inflammatory processes with a technetium-99-m-labelled monoclonal antigranulocyte antibody (MAb BW 250/183). *J Nucl Med* 1990;31:417-23.
18. Hotze AL, Briete B, Overbeck B, et al. Technetium-99m-labelled anti-granulocyte antibodies in suspected bone infections. *J Nucl Med* 1992;33:526-31.
19. Oyen WJG, Boerman OC, van der Laken C, Calessens RAMJ, van der Meer JWM, Corstens FJM. The uptake mechanisms of inflammation and infection-localizing agents. *Eur J Nucl Med* 1996;23:459-65.
20. Pons F, Sanmarti R, Herranz R, Collado A, Piera C, Vidal-Sicart S, Munoz-Gomez J, Setoain J. Scintigraphic evaluation of the severity of inflammation of the joints with  $^{99m}\text{Tc}$ -HIG in rheumatoid arthritis. *Nucl Med Commun* 1996;17:523-8.
21. Demirkol MO, Adalet I, Unal SN, Tozun R, Cnatez S.  $^{99m}\text{Tc}$ -polyclonal IgG scintigraphy in the detection of infected hip and knee prostheses. *Nucl Med Commun* 1997;18:543-8.
22. Palermo F, Boccaletto F, Paolin A, et al. Comparison of Technetium-99m-MDP, Technetium-99m-WBC and Technetium-99m-HIG in Musculoskeletal Inflammation. *J Nucl Med* 1998;39:516-21.
23. Ang Es, Sundram FX, Goh ASW, AW SE.  $^{99m}\text{Tc}$ -polyclonal IgG and  $^{99m}\text{Tc}$  nanocolloid scans in orthopaedics: a comparison with conventional bone scan. *Nucl Med Commun* 1993;14:419-32.
24. Guhlmann A, Brecht-Krauss D, Suger G, et al. Fluorine-18-FDG PET and Technetium-99m Antigranulocyte Antibody Scintigraphy in Chronic Osteomyelitis. *J Nucl Med* 1998;39:2145-52.
25. Lonneux M, Sibomana M, Pauwels S, Gregoire V. Current data and perspectives on positron emission tomography oncology-radiation therapy. *Cancer-Radiother* 1999;3(4):275-88.
26. Britton KE, Vinjamuri S, Hall AV, Solanki K, Siraj QH, bomanji J, Das S. Clinical evaluation of technetium-99m infecton for the localisation of bacterial infection. *Eur J Nucl Med* 1997;24(5):553-6.