

## Case Report

---

# Imaging findings of spontaneous thymic hemorrhage in infancy: Case report and literature review

*Chanunporn Leekumnerdthai, M.D.<sup>(1)</sup>*

*Panruethai Trinavarat, M.D.<sup>(2)</sup>*

*Darintr Sosothikul, M.D.<sup>(3)</sup>*

*Nattinee Leelakanok, M.D.<sup>(4)</sup>*

From <sup>(1)</sup>Department of Radiology, Bhumibol Adulyadej Hospital, The Royal Thai Airforce, Bangkok, Thailand.

<sup>(2)</sup>Department of Radiology, Faculty of Medicine, Chulalongkorn University, Bangkok, Thailand.

<sup>(3)</sup>Department of Pediatrics, Faculty of Medicine, Chulalongkorn University, Bangkok, Thailand.

<sup>(4)</sup>Department of Radiology, Faculty of Medicine, Chulalongkorn University and King Chulalongkorn Memorial Hospital, Bangkok, Thailand.

Address correspondence to C.L. (e-mail: chalee507@hotmail.com)

## Abstract

The authors report imaging findings of spontaneous thymic hemorrhage, which is a rare entity in infancy, in a 4-month-old boy with congenital factor VII deficiency presented with acute respiratory distress and anemia. Widening of superior mediastinum and left pleural effusion were detected on the chest radiograph. Ultrasound and computed tomography of the chest revealed diffusely enlarged thymus with heterogeneous parenchyma from poorly-defined areas of altered echogenicity or attenuation. Vascular flow was depicted within the abnormal thymus in color-mode sonography. The spontaneous involution of thymic abnormality seen on serial ultrasonography confirmed the diagnosis of thymic hemorrhage, resulting in avoidance of further unnecessary imaging or invasive procedure.

**Keywords:** Thymic hemorrhage, Spontaneous hemorrhage, Bleeding tendency, Factor 7 deficiency, Infancy, Thymus.

## Introduction

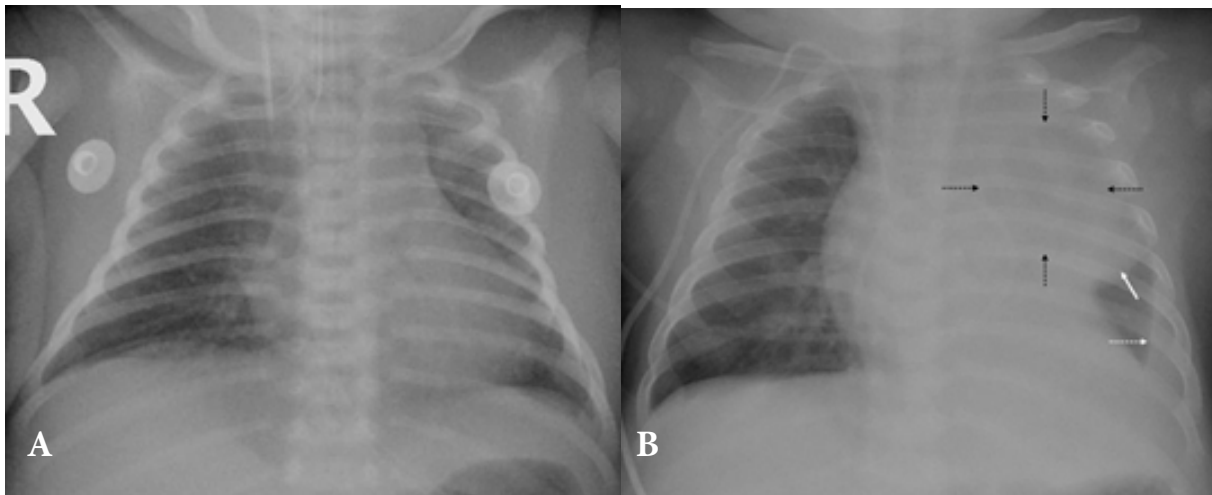
A normal thymus gland in children may occupy a large proportion of mediastinum, seen on a chest radiograph without causing symptoms. Normal thymus from ultrasonography shows rather homogeneous medium-echogenicity with some high-echogenic dots and short strands, and minimal internal vascular flow[1]. Normal thymus from CT reveals homogeneous density with mean attenuation value of about 36 HU on unenhanced phase, and homogeneous enhancement after intravenous contrast media injection[2]. Spontaneous thymic hemorrhage is very rare in pediatrics, and even rarer in adults, but it could be a life-threatening condition. The etiology of thymic hemorrhage is usually unidentified, but bleeding diathesis particular from vitamin K deficiency is mostly believed to be the cause in neonates and young infants. Due to its rarity, there are not many reports of its imaging findings. To our knowledge, there were eight reported cases of spontaneous hemorrhage in normal thymus with presence of imaging findings in perinatal and infantile period[3-9], and only three reports in adults[10-12] in English literature. The authors report a 4-month-old boy with thymic hemorrhage from congenital factor VII deficiency and describe imaging findings of his thymus.

## Case report

A 4-month-old boy was presented with fever, irritability and poor feeding for 3 days. He was first admitted to the hospital at age of 4-day old due to acute subdural hemorrhage and had been diagnosed with congenital factor VII deficiency. His blood tests at that time showed anemia (hemoglobin 7.4 g/dl), a low level of platelet count (134,000/mcL), isolated prolonged prothrombin time and a low level of factor VII (<1%). The duration of the first admission was 31 days. The treatment after discharge was regular fresh frozen plasma (FFP) 10 mg/kg intravenously, three times a week.

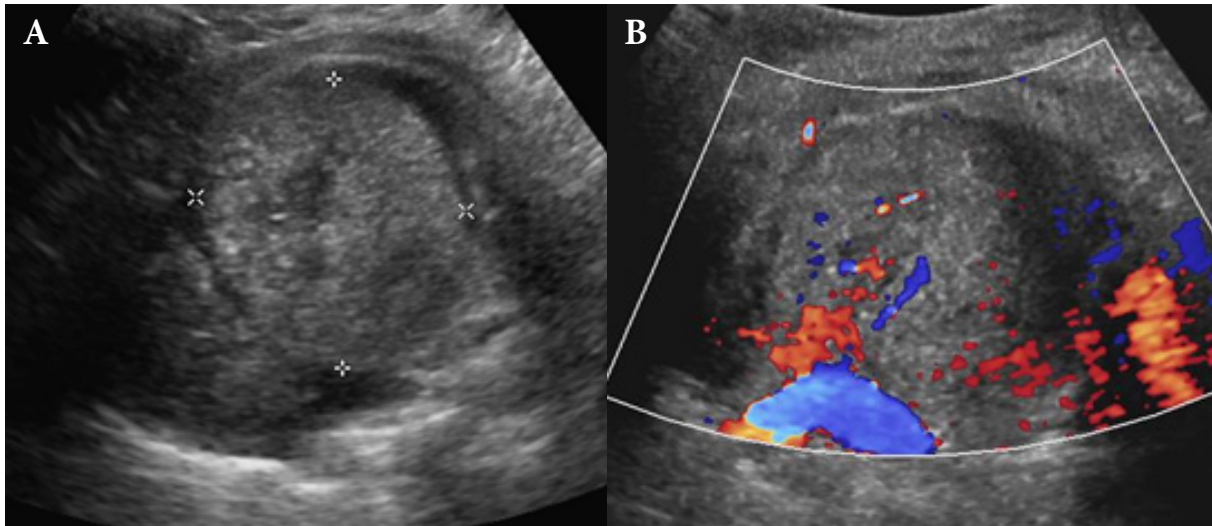
This time was his second admission. His blood tests showed anemia (hemoglobin 7 g/dl), a mildly elevated white blood count (10,370/mcL) and a

normal platelet count (397,000/mcL). A 2-mm-thick acute subdural hematoma at the right parietal convexity was detected from the CT scan of the brain. On the next day, he developed tachypnea with a respiratory rate of 60/min, with subcostal retraction and a decreased breath sound of the left lung. His chest radiograph showed a widened left side of superior mediastinum, partial atelectasis of the left upper lobe, and the left pleural effusion with obscuration of the left hemidiaphragm. These abnormalities were not seen on his chest radiograph during his first admission (Figure 1). The cause of the mediastinal widening was uncertain, and the differential diagnoses were mediastinal hemorrhage, mediastinal mass, and rebound thymic hyperplasia.



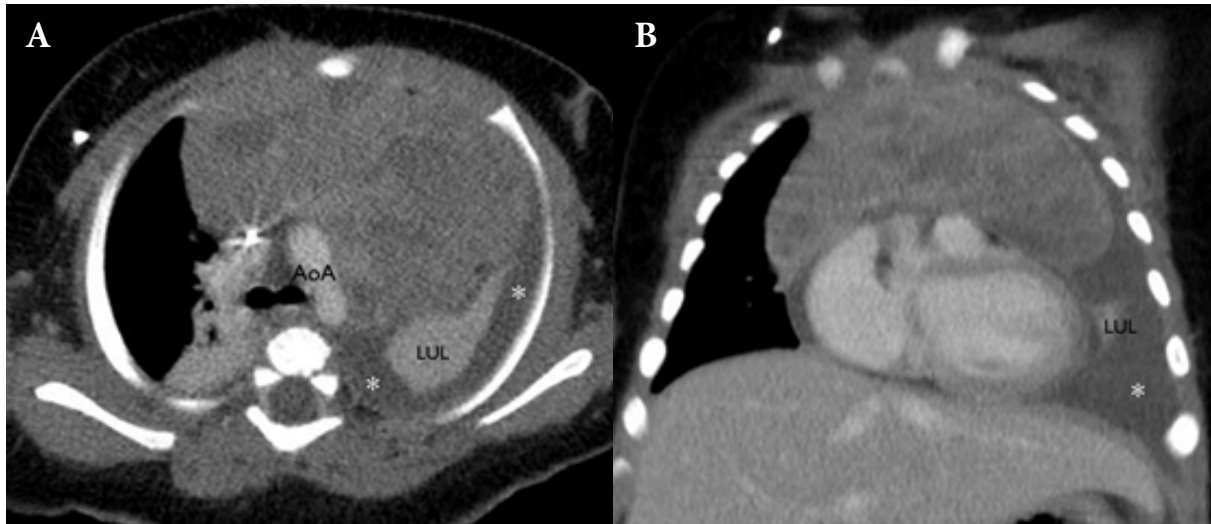
**Figure 1.** The chest radiograph of the 11-day old (A) from the first admission showed a normal cardiac size, small thymic shadow, and clear lungs. The chest radiograph on the second admission at the age of 4 months (B) showed a widened left side of the mediastinum reaching the lateral chest wall with an inferior bulging contour (white arrow). There was partial atelectasis of the left upper lobe with a small area of aerated lungs (black dashed arrows) superimposed on the lesion. There was the left pleural effusion (white dashed arrow) causing obliteration of the left hemidiaphragm and the left costophrenic angle.

Chest ultrasonography on the same day revealed a large heterogeneously-echogenic mass in the left thymic lobe, with a few vascular flows within that thymic lesion (Figure 2).



**Figure 2.** The ultrasonography of the chest (A) showed a 4.7x4.4 cm heterogeneous hyperechoic mass-like lesion in the location of the left thymic lobe. (B) There were a few foci of vascular flow within the lesion in color-mode sonography.

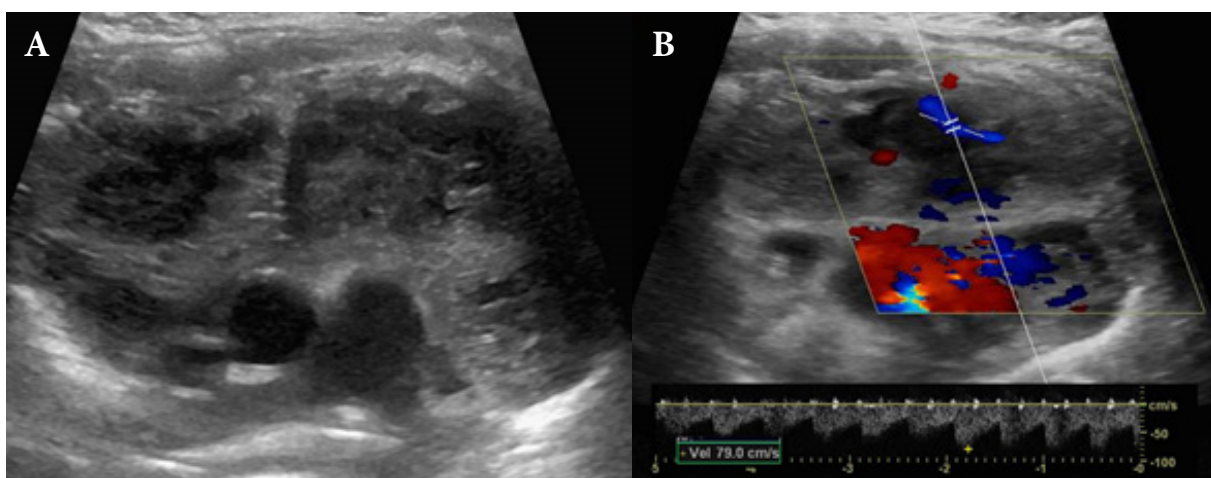
The single-venous-phased CT scan of the chest on the same day showed an enlarged thymus gland with preservation of a thymic shape, but had heterogeneous parenchymal enhancement with multifocal poorly-defined areas of hypodensity (Figure 3). The attenuation values of the areas of hypodensity and hyperdensity were 57 HU (probably a recent hemorrhage) and 89 HU (probably an enhanced thymic tissue), respectively. Complete atelectasis of the left lung and the left pleural effusion were spotted.



**Figure 3.** The venous-phased chest CT in axial (A) and coronal planes (B) revealed an enlarged thymus, particularly the left lobe, with preservation of a thymic shape. Measured in axial plane, transverse diameter = 79 mm (normal =  $39.6 \pm 5.5$  mm in 4-5 months of age), right lobe thickness = 34 mm (normal =  $19.5 \pm 5.7$  mm) and left lobe thickness = 51 mm (normal =  $22.5 \pm 3.8$  mm) [13]. Poorly-defined multifocal areas of hypodensity (57 HU) were noted within the relatively more enhanced areas (89 HU). The left pleural effusion (\*) and atelectasis of the left upper lobe (LUL) were also presented (AoA = aortic arch).

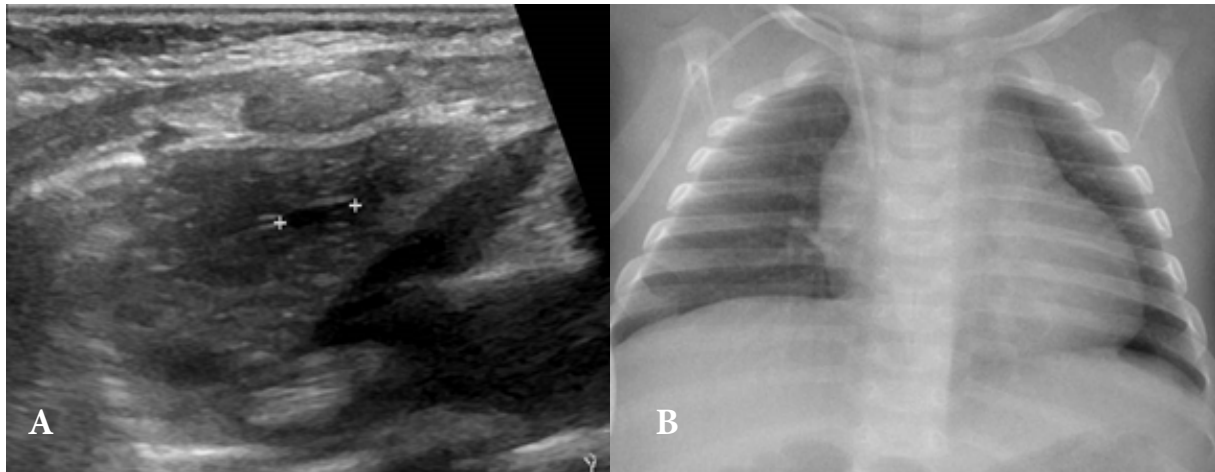
According to a new acute subdural hematoma, anemia, and his underlying factor VII deficiency, the thymic abnormality was suggested to be thymic hemorrhage. The patient was treated with intravenous FFP 10 mg/kg/dose every 6 hours. There was a concern of minimal demonstrable vascular flow within the thymic lesion from the ultrasound, whether there was an infiltrative thymic tumor that may need thymic biopsy or not. A serial follow-up with ultrasound was planned.

The first follow-up ultrasound at a 5-day interval showed a decreased size and internal echogenicity with development of some internal small cysts (Figure 4). The findings indicated partial resolution of multifocal hematomas within the thymus gland. The vascular flow was still detected within these lesions, showing a low-resistant waveform.



**Figure 4.** *The first follow-up ultrasound at 5-day interval (A) showed decreased size, less echogenicity, and more well-defined border of the multifocal thymus lesions. (B) Vascular flow within the lesion had low-resistant waveform.*

A subsequent follow-up chest ultrasound at 3-week interval showed a further decrease in size of the thymus with residual minimal heterogeneity and tiny cystic areas. His chest radiograph on the same day looked normal (Figure 5).



**Figure 5.** *The subsequent 3-week follow-up chest ultrasound (A) showed thymic gland returning to a nearly normal size with residual tiny cystic areas. His chest radiograph on the same day (B) showed normal cardiothymic shadow, complete resolution of the left pleural effusion, and well-aerated lungs.*

His clinical symptoms were resolved without other bleeding sites. Blood tests were repeated before discharge and showed normal values. The duration of his second admission was 14 days.

## Discussion

Thymic hemorrhage, although rare, is an important life-threatening condition. When a spontaneous hemorrhage in a normal thymus (SHNT) occurs in the perinatal and infantile age group, the most common postulated etiology is vitamin K deficiency (formerly known as a hemorrhagic disease of the newborn) [9]. Besides clinical findings of acute respiratory distress and anemia, imaging adds an important role in supporting the diagnosis of the thymic hemorrhage.

The frontline imaging modality is usually a chest radiograph. As a normal thymus in infants can be widely variable in size and shape, it may be difficult to differentiate a normal or rebound hypertrophic thymus from pathologic thymic entities without adding other imaging investigations. The echogenicity in ultrasound or homogeneous density in CT can differentiate between rebound thymic hyperplasia and an enlarged thymic hemorrhage. The rebound thymic hyperplasia still preserves a normal 'starry sky' appearance while the thymic hemorrhage does not. Again the thymic hemorrhage shows heterogeneous hyper-attenuation on the CT scan while the rebound thymic hyperplasia does not.

The affected 4-month-old boy with congenital factor VII deficiency had the second episode of symptomatic intracranial bleeding and the first episode of thymic bleeding. His chest radiography showed widened superior mediastinum without an identified cause. The ultrasonographic findings showed a loss in 'starry sky' appearance of normal thymus and presence of a mass-like lesion in left thymic lobe, so thymic hemorrhage was considered. The possibility of hyperechoic thymic tumor was raised when the radiologist detected minimal vascular flow within the hyperechoic thymic mass. From the single venous-phased chest CT in this case, the retained thymic shape and the alternating areas of hypo- and hyper-density suggested the possibility of hematomas (57 HU) among the enhanced thymic tissue (89 HU). Performing a pre- and post-contrast enhanced chest CT would be easier to diagnose a thymic hemorrhage, but it was not recommended to perform it with infants and small children due to increased radiation exposure. The clinical context and serial follow up imaging with ultrasound is the best management. This could obviate the need for biopsy, surgery, or any further CT or MR imaging.

Imaging findings in the nine cases of SHNT in perinatal and infantile period [3-9], this report included, are summarized in Table 1-2. Four of them were presented in a very early neonatal period and the other five cases were presented in an early infantile period (between the age of 4 weeks and 4 months). All reported cases mentioned non-specific enlarged antero-superior mediastinum in chest radiographs; seven of the nine cases had associated pleural effusion, preferential



on the left side or both sides. Two had pericardial effusion detected by the ultrasound. Pleural effusion was proven to be hemothorax in patients who had the effusion drained. In the three cases having surgical thymectomy, pleural perforation was detected in two of them.

**Table 1.** Demographic data and chest radiographic findings of SHNT from literature review and this case report.

Case no.	Year reported	Author	Gender	Age	Surgery	Coagulo-pathy*	Outcome	Chest radiograph			Other imaging evaluation	
								Mediastinal widening	Pleural effusion			
									Bilateral	Left only	None	
1	1974	Wooley (3)	F	2 days	Thymectomy	-	Survive	√		√		-
2	1974	Wooley (3)	M	4 weeks	Thymectomy	√	Survive	√		√		-
3	1989	Lemaitre (4)	M	2 months	-	√	Survive	√	√			US
4	1994	Urvoas (5)	M	4 weeks	-	√	Survive	√			√	US
5	1996	Walsh (6)	M	Perinatal	-	-	Die	√			√	-
6	1997	Bees (7)	F	Perinatal	Thymectomy	X	Survive	√		√		US, CT
7	2015	Gargano (8)	M	Perinatal	-	√	Survive	√	√			US, CT, MRI
8	2017	Palau (9)	M	4 weeks	(Biopsy, US guidance)	√	Survive	√	√			US, CT
9	2019	This report	M	4 months	-	√	Survive	√		√		US, CT

\* Coagulopathy in case number 2,3,4,7,8 was believed to be from vitamin K deficiency, and in case number 9 is Factor VII deficiency.

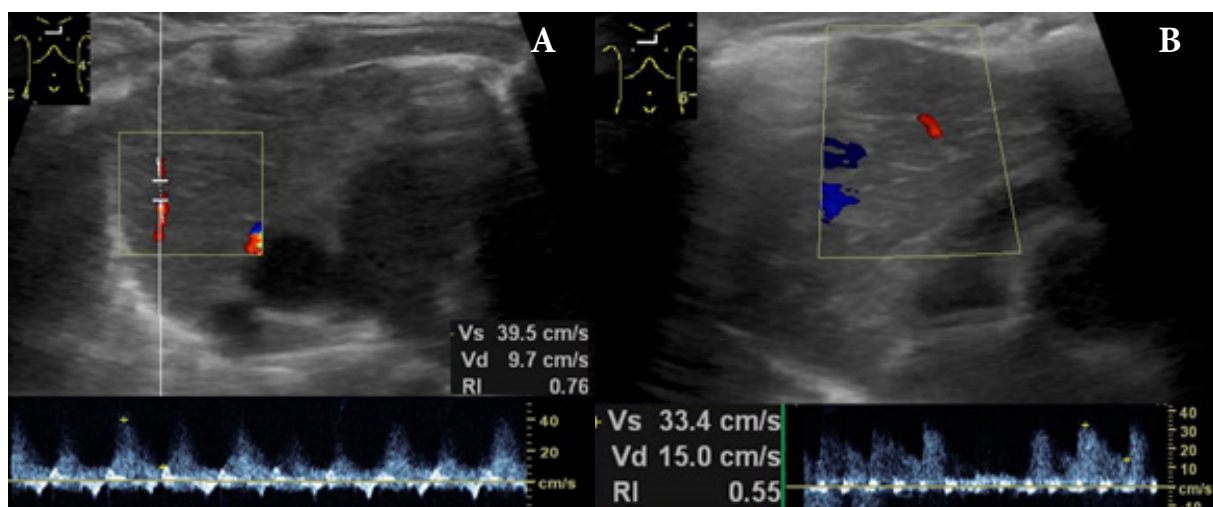
Ultrasound, from its wide availability, portability and nowadays a good resolution, is suitable to be the next imaging tool after the chest radiograph in this clinical scenario to reveal the location and the solid or cystic nature of the lesion. Vascular malformation or a teratoma may be suspected if there is a cystic component or calcification. Ultrasound findings performed in six of the nine cases of a thymic hemorrhage (table 2) showed solid lesions with heterogeneous echotexture. Focal

nodular lesion(s) of either hyper- or hypo-echogenicity, or bulls' eye appearance, were found, depending on the chronology of the hemorrhage. The presence of a few foci of vascular flow within the lesion cannot rule out the thymic hemorrhage, as evidence in this reported case. Therefore, ultrasound findings were nonspecific, and hardly possible to be differentiated from other rare thymic or anterior mediastinal tumors in this age group such as Langerhans cell histiocytosis, lymphoma, or hemorrhage of other underlying thymic lesions.

**Table 2.** Findings from ultrasonography, CT, and MRI of SHNT from literature review and this case report.

Case no.	Echotexture	Ultrasound			Other findings	CT and MRI findings
		Focal nodule(s) Hypo	Hyper	Bulls' eye		
3	Heterogeneous	√	√		-	
4	Heterogeneous	√		√	Mass effect on LBCV	-
6	Heterogeneous		√			CT - Large anterior mediastinal mass, inhomogeneous attenuation, did not enhanced with contrast medium, with mass effect on left main bronchus
7	Heterogeneous		√		Small pericardial effusion	CT - Enlarged thymus, mainly left side with tracheal displacement to the right, hyperdensity areas on NECT, non-homogeneous on CECT MRI (day 10) - Very reduced size of the thymus, homogeneous structure with hyperintense signal in T1 and T2 sequences (subacute hemorrhage)
8	Not described	Solid mass, detail not described			Minimal ascites modest pericardial effusion	CT - Homogeneously enhancing anterior mediastinal mass of thymic contour, with mass effect on the vessels and airway
9	Heterogeneous		√		A few internal vascular flows in the nodule	CT - Enlarged thymus, heterogeneous enhancement (NECT not performed)

Follow-up thymic lesion(s) with the ultrasound to confirm a complete resolution in case of hemorrhage is noninvasive and simple. The thymic hemorrhage in this reported case, after control of coagulopathy, showed a partial resolution within 5 days, seen as better delineation and decreased echogenicity of an internal hemorrhage, or an early small cystic change. Vascular flow was still noted within the resolving thymic hematoma, showed a low-resistant waveform. In further follow-ups, the thymus gland gradually returned to nearly normal echogenicity, but atrophic, and the internal flow was hardly detected. After seeing this case, one of the authors performed color Doppler ultrasound on the normal thymus of the two neonates which revealed a few foci of vascular flows with a low-resistant waveform (Figure 6). So the vascular flow demonstrable in area of thymic hemorrhage could be a normal intra-thymic vessel.



**Figure 6.** Color Doppler sonography of normal thymus in a 2-month-old boy (A) and another 4-month-old boy (B) revealed a few intra-thymic artery with low-resistant waveform.

From the literature review and this case report, the CT scan better provided the overview of the entire thymus[2]. It showed a retained thymic shape, and detected hyper-attenuated area of hemorrhage in a non-contrast scan that did not enhance after the contrast injection. However, it cannot rule out a thymic tumor with bleeding or may have inconclusive result if there is no hyper-attenuated area of an acute hemorrhage (probably from severe anemia or subacute hemorrhage). Although both ultrasound and CT were performed, biopsy was still required in one case to rule out underlying thymic pathology.

MRI was performed in only one case of the thymic hemorrhage[8], showing subacute hematoma within the thymus on the sixteenth day after the onset of the bleeding. MRI can be excellent in confirming and dating thymic hemorrhage, and also excluding an underlying thymic tumor. However, a long imaging time of MRI prohibits its use in emergent unstable patients.

The management of an infantile thymic hemorrhage usually started with normalization of coagulation indices by giving vitamin K and fresh frozen plasma, and adding packed red cell to the anemic ones[3-9]. The coagulopathy was usually corrected within 6-24 hours. Thymectomy was indicated when the respiratory distress was severe due to airway compression[3]. Thymectomy or biopsy under an imaging guidance was also performed when suspicious of a thymic tumor[7,9].

In conclusion, although the thymus is an uncommon target organ of bleeding in coagulopathy compared to the brain or gastrointestinal tract, this possibility should not be overlooked. Almost all of the imaging findings were abnormal widened superior mediastinum with or without pleural effusion found on the chest radiograph, heterogeneous thymus with hyper- or hypoechoic nodule(s) on ultrasound and thymic enlargement with heterogeneous densities on CT images. The presence of intralesional vascularity on color Doppler sonography could not rule out the thymic hemorrhage. An ultrasound can be used as a mainstay modality to show the abnormality, to follow up the resolution, and to avoid further unnecessary imaging or invasive procedures.

## References

1. Han BK, Suh YL, Yoon HK. Thymic ultrasound. I. Intrathymic anatomy in infants. *Pediatr Radiol* 2001;31:474-9.
2. Webb WR. The mediastinum: mediastinal masses. In: Webb WR, Higgins CB. *Thoracic imaging: pulmonary and cardiovascular radiology*. 2 nd ed. Philadelphia PA: Lippincott Williams & Wilkins; 2011. p.219-85.
3. Woolley MM, Isaacs H Jr, Lindesmith G, Vollmer DM, Van Adelsberg S. Spontaneous thymic hemorrhage in the neonate: report of two cases. *J Pediatr Surg* 1974;9:231-3.
4. Lemaitre L, Leclerc F, Dubos JP, Marconi V, Lemaire D. Thymic hemorrhage: a cause of acute symptomatic mediastinal widening in an infant with late haemorrhagic disease. Sonographic findings. *Pediatr Radiol* 1989;19:128-9.
5. Urvoas E, Pariente D, Rousset A, De Victor D, Leblanc A. Ultrasound diagnosis of thymic hemorrhage in an infant with late-onset hemorrhagic disease. *Pediatr Radiol* 1994;24:96-7.
6. Walsh SV, Cooke R, Mortimer G, Loftus BG. Massive thymic hemorrhage in a neonate: an entity revisited. *J Pediatr Surg* 1996;31:1315-7.
7. Bees NR, Richards SW, Fearne C, Drake DP, Dicks-Mireaux C. Neonatal thymic haemorrhage. *Br J Radiol* 1997;70:210-2.
8. Gargano G, Paltrinieri AL, Gallo C, Di Pancrazio L, Roversi MF, Ferrari F. Massive thymic hemorrhage and hemothorax occurring in utero. *Ital J Pediatr* 2015 Nov14;41:88. doi: 10.1186/s13052-015-0196-5.

9. Palau MA, Winters A, Liang X, Nuss R, Niermeyer S, Gossling M, et al. Vitamin K deficiency presenting in an Infant with an anterior mediastinal mass: A case report and review of the literature. *Case Rep Pediatr* 2017;2017: 7628946. doi: 10.1155/2017/7628946.
10. Ghoshhajra K. Spontaneous thymic hemorrhage in an adult. *Chest* 1977;72: 666-8.
11. Sakuraba M, Tanaka A, Tsuji T, Mishina T. Spontaneous thymic hemorrhage in an adult. *Ann Thorac Surg* 2014 May;97(5):1800-2. doi: 10.1016/j.athoracsur.2013.07.098.
12. de Perrot M, Bründler MA, Girardet C, Spiliopoulos A. Spontaneous hemorrhage of thymus and thymoma in adults. *Eur J Cardiothorac Surg* 1999;16:674-6.
13. Yekeler E, Tambag A, Tunaci A, Genchellac H, Dursun M, Gokcay G, et al. Analysis of the thymus in 151 healthy infants from 0 to 2 years of age. *J Ultrasound Med* 2004;23:1321-6.