
FOCUSED ASSESSMENT WITH SONOGRAPHY FOR TRAUMA (FAST) PERFORMED BY EMERGENCY MEDICINE RESIDENTS AT NOPPARAT RAJATHANEE HOSPITAL

Chuda SRISUKONTH, M.D.¹

ABSTRACT

Focused Assessment with Sonography for Trauma or FAST is an excellent initial screening test for assessment of trauma patients. Nowadays, FAST performed by non-radiologist clinicians is widely accepted. At Nopparat Rajathanee Hospital, FAST training is offered to our emergency medicine residents in order to compare and discussed the results to those performed by experienced radiologists.

The study took place from January to September 2005 which FAST exams were performed on thirty patients by two emergency medicine residents using experienced radiologists as a gold standard. The findings are as followed: 84.21% sensitivity, 90.90% specificity, 86.66% accuracy, 94.11% positive predictive value and 76.92% negative predictive value.

FAST performed by emergency medicine residents is satisfactory in general. It is considered sufficient as a screening test. Nevertheless, in some cases with negative results, further diagnostic workup is recommended.

INTRODUCTION

During the past several years, the number of trauma patients has increased. Rapid diagnoses and treatments have played a significant role in mortality and morbidity rate reduction. Physical examination alone has proven to be frequently unreliable in the diagnosis for trauma patients especially when they are unconscious or when there are multiple injuries.^{1,2} Focused Assessment with Sonography for Trauma or FAST is widely accepted as the effective mean for a screening test.³⁻⁶ Currently at Nopparat Rajathanee Hospital, radiologists are not available around the clock to perform FAST. However, it has become acceptable and reasonable for trained emergency physicians and trauma surgeons to perform FAST reliably.^{2,7-12} The accuracy rate of their results is

reportedly very close to those performed by radiologists.^{13,14} Nevertheless, there has been ongoing discussion on the minimum number of FAST cases performed by the emergency physicians and surgeons during their training to become competent and the FAST training curriculum itself.^{15,23}

Nopparat Rajathanee Hospital has been offering the trial FAST training to emergency medicine residents. The objective of the study is to compare the FAST results performed by trained emergency medicine residents and experienced radiologists (performed more than 4,000 comprehensive sonography).

¹ Radiology Department, Nopparat Rajathanee Hospital, Bangkok, Thailand

PATIENTS AND METHODS

The study has been conducted from January through September 2005. Initially, the training was offered to two emergency medicine residents. The

program is modified from those offered at the University of Vermont¹⁵ shown in Table 1.

Table 1 Standard for performance and interpretation of FAST training at Nopparat Rajathanee Hospital

<p>Phase I</p> <p>Three hours of continuing medical education in ultrasound</p> <p>The topics to be considered include:</p> <ol style="list-style-type: none"> 1. Physics <ol style="list-style-type: none"> a. Fundamental of the ultrasound wave b. Pulse echo principle c. Angle of ultrasound beam d. Acoustic impedance/tissue density attenuation-absorption and scatter 2. Instrumentation <ol style="list-style-type: none"> a. Transducer frequency-effect on resolution and penetration b. Gain/attenuation c. Power, depth, and magnification d. Image orientation e. Image display-freeze frame and real time modes <p>Phase II</p> <p>Three hours of practical training of normal patients with negative results</p> <p>Phase III</p> <p>Three hours of practical training on ascites patients with positive results</p>

Phase I lasts three hours. This segment includes physics of ultrasound wave, instrumentation, basic knowledge in performing FAST and result interpretation.

Phase II lasts three hours as a practical training. Participants have a hand-on FAST examination on four healthy volunteers whose results are only negative.

Phase III lasts three hours as yet another practical training. At this time, however, participants perform FAST on four ascites patients whose results are only positive.

After the completion of the 3 Phases training

mentioned above, during official hours when both emergency residents and radiologists are available, and when it does not interfere with patient management. In the case of trauma patients, the study is performed during the secondary survey of Advanced Trauma Life Support (ATLS) by using the Aloka SSD -1100 (Japan) ultrasound machine available in the Emergency Department. In non-trauma cases, patients with possible ascites such as those with cirrhosis, hypoalbuminemia or chronic renal failure are selected. The studies took place at the Radiology Department using the B-K 3535-B08 (Denmark) ultrasound machine with 3.5 or 5 MHz. transducer.

The application of transducer is based on what recommended by Ma OJ, et al.¹⁶ The transducer is

placed on subxyphoid region (1), right upper quadrant (2), right flank (3), left upper quadrant (4), left flank (5) and suprapubic region (6) in order to find fluid in pericardial space, hepatorenal fossa, right paracolic space, splenorenal space, left paracolic space and pelvic cavity respectively as shown in Figure 1.

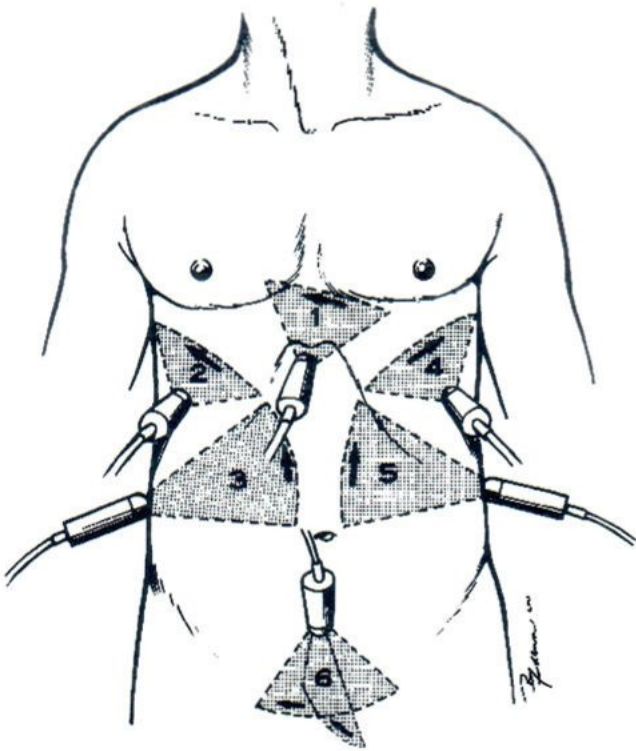


Fig. 1 Application of transducer for FAST recommended by Ma OJ, et al.

One of the two of emergency residents periodically report results either negative or positive for each point of every peritoneal space mentioned above. Radiologists then perform the FAST exams using the same ultrasound machine after emergency

residents have completed their tasks. At this point, radiologists are not aware of the results performed by emergency residents. Once both teams have completed, their results are compared. If there are discrepancy on their results in one or more peritoneal spaces, the FAST exams are performed again by emergency residents under the supervision of radiologists for proctor purposes only.

The FAST result is considered positive when fluid is found in one or more spaces while it is considered negative when fluid is not found in any space at all.

The FAST results performed by emergency residents upon their training completion are analyzed using standard formulas¹⁷ for sensitivity, specificity, accuracy, positive predictive value, negative predictive value, using experienced radiologists' results as the gold standard.

RESULTS

FAST exams are performed on thirty patients: 20 male (66.66%) and 10 female (33.33%). The average age of the patients is 41.97±15.72 years old. There are 14 non-trauma (46.66%) and 16 trauma (53.33%) patients. The causes of injuries were seven motor vehicle accidents, four fall from heights, four hit by objects and one assault.

The comparison of FAST results performed by two emergency residents and radiologists is shown in Table 2. There are sixteen true positive, ten true negative, one false positive and three false negative cases. Prevalence, sensitivity, specificity, accuracy, positive predictive value and negative predictive value of FAST results are shown in Table 3.

Table 2 FAST results and scan time performed by emergency residents (er) and radiologists (R)

Patients	Age(y)	Sex	History	Subxyphoid		Hepatorenal		Rt.paracolic		Splenoarenal		Lt.paracolic		Pubis		FAST results		Scan time		
				er	R	er	R	er	R	er	R	er	R	er	R	er	R	er	R	er
1	41	m	fall from height	n	n	p	p	p	p	p	p	p	p	p	p	p	TP	TP	8	3
2	42	m	fall from height	n	n	p	p	p	p	p	p	p	p	p	p	p	TP	TP	7	3
3	43	m	hit by object	n	n	n	n	n	n	n	n	n	n	n	n	n	N	TN	10	3
4	43	m	fall from height	n	n	n	n	n	n	n	n	n	n	n	n	n	N	TN	11	3
5	34	m	assault	n	n	p	p	p	p	p	p	p	p	p	p	p	P	TP	16	5
6	40	m	hit by object	n	n	n	n	n	n	n	n	n	n	n	n	n	N	FN	10	3
7	28	f	motor vehicle accident	n	n	n	n	n	n	n	n	n	n	n	n	n	N	FN	7	3
8	54	m	motor vehicle accident	n	n	p	p	p	p	p	p	p	p	p	p	p	P	TP	10	4
9	19	m	hit by object	n	n	p	p	p	p	p	p	p	p	p	p	p	P	TP	8	4
10	43	f	nontrauma	n	n	p	p	p	p	p	p	p	p	p	p	p	P	TP	8	4
11	32	f	motor vehicle accident	n	n	n	n	n	n	n	n	n	n	n	n	n	N	TN	5	3
12	22	m	fall from height	n	n	p	p	p	p	p	p	p	p	p	p	p	P	TP	7	3
13	48	m	nontrauma	n	n	n	n	n	n	n	n	n	n	n	n	n	N	TN	6	4
14	27	f	motor vehicle accident	n	n	n	n	n	n	n	n	n	n	n	n	n	N	TN	10	3
15	51	m	motor vehicle accident	n	n	p	p	p	p	p	p	p	p	p	p	p	P	TP	10	4
16	15	m	hit by object	n	n	p	p	p	p	p	p	p	p	p	p	p	P	TP	9	4
17	42	f	nontrauma	n	n	n	n	n	n	n	n	n	n	n	n	n	N	TP	8	4
18	29	f	nontrauma	n	n	n	n	n	n	n	n	n	n	n	n	n	N	TP	5	3
19	59	m	nontrauma	n	n	n	n	n	n	n	n	n	n	n	n	n	N	FN	5	3
20	22	m	nontrauma	n	n	n	n	n	n	n	n	n	n	n	n	n	N	TN	5	2
21	73	m	nontrauma	n	n	n	n	n	n	n	n	n	n	n	n	n	N	TN	5	3
22	43	f	nontrauma	n	n	n	n	n	n	n	n	n	n	n	n	n	N	TN	8	3
23	44	m	nontrauma	n	n	n	n	n	n	n	n	n	n	n	n	n	N	TN	6	3
24	38	m	nontrauma	n	n	n	n	n	n	n	n	n	n	n	n	n	N	TN	5	2
25	57	m	nontrauma	n	n	p	p	p	p	p	p	p	p	p	p	p	N	FP	5	2
26	81	m	motor vehicle accident	n	n	n	n	n	n	n	n	n	n	n	n	n	N	TN	9	4
27	44	f	nontrauma	n	n	n	p	p	p	p	p	p	p	p	p	p	P	TP	8	3
28	56	f	nontrauma	n	n	n	n	n	n	n	n	n	n	n	n	n	N	TN	6	2
29	21	m	motor vehicle accident	n	n	p	p	p	p	p	p	p	p	p	p	p	P	TP	7	3
30	68	f	nontrauma	n	n	p	p	p	p	p	p	p	p	p	p	p	P	TP	5	3

P = Positive, **N** = Negative, **TP** = True Positive, **TN** = True Negative, **FN** = False Negative

Table 3 Summary of findings

Number of patients enrolled	30
True positives	16
True negatives	10
False negatives	3
False positive	1
Prevalence	63.33%
Sensitivity	84.21%
Specificity	90.90%
Accuracy	86.66%
Positive predictive value	94.11%
Negative predictive value	76.92%
Scan time	
Emergency residents	7.63±2.44 mins
Radiologists	3.2±.70 mins

DISCUSSION

FAST examination is technically distinct from comprehensive diagnostic sonography in which diagnoses are often entertained and formally accepted. It is a clinically focused sonography performed in trauma patients to answer a specific question that is whether the fluid that represents hemoperitoneum present or not.

Although sonography has been used for the torso evaluation of trauma patients by surgeons in Japan and in Europe especially Germany for three decades, FAST was initially developed and designed principally for non-radiologists by Rozycki et al.^{11,20} in 1993 and has only been gaining popularity during the last decade.^{9,18,19}

It has been reported that the FAST results performed by well-trained non-radiologist clinicians are satisfactorily parallel to those performed by the radiologists.¹³⁻¹⁴

The result of our study is relatively close to the studies of those who have been well-trained.^{13,23} The high expectation of our results may be due to:

1. The result of gold standard selection. In the studies where sensitivity and specificity are high, the low sensitivity tests such as clinical outcomes are usually selected as one of the gold standards. Radiologists are certainly among the low sensitivity tests unlike diagnostic peritoneal lavage (DPL) and CT scan.
2. High sample prevalence of 63.33% comparing to 5-43% of other studies.^{21,22} High prevalence means high number of positive cases. This may result in steep learning curve which allows us to reduce the number of cases in FAST training to achieve satisfactory level.
3. Long scan time. The average scan time in our study is 7.63±2.44 minutes as compared to less than four minutes by others.^{18,23,24} Our long scan time is likely to yield more accurate results which make our emergency residents appear to be skillful and well-trained.

Nevertheless, negative predictive value is 76.92% which is not very high. This means only 76.92% of patients with negative FAST exams have no hemoperitoneum. For this reason, further diagnostic workup such as DPL or CT scan is recommended.

CONCLUSION

At Nopparat Rajathanee Hospital, the FAST examination and interpretation training is offered to emergency medicine residents. We have found that their results are satisfactorily accurate and reliable in comparison with the results of experienced radiologists. This means that their FAST exams can be used as the primary screening test at some levels of confidence. However, even with negative FAST results especially in the patients who might have intra-abdominal injury, further diagnostic workup is recommended.

ACKNOWLEDGEMENTS

I would like to express my appreciation to Dr. Waranchai Mukbundidpong and Dr. Chonlada Pongratanamarn, our emergency medicine residents for being such attentive sonographers.

REFERENCES

1. Schurink GW, Bode PJ, van Luijt PA, et al. The value of physical examination in the diagnosis of patients with blunt abdominal trauma: a retrospective study. *Injury* 1997; 28: 261-265.
2. Röthlin MA, Naf R, Amgwerd M, et al. Ultrasound in blunt abdominal and thoracic trauma. *J trauma* 1993; 34: 488-495.
3. McKenney MG, Lentz KA, Nunez DB, et al. Can ultrasound replace diagnostic peritoneal lavage in the assessment of blunt trauma? *J Trauma* 1994; 37: 439-441.
4. Poletti P-A, Wintermark M, Schnyder P, et al. Traumatic injuries: role of imaging in the management of the polytrauma victim (conservative expectation). *Eur Radiol* 2002; 12: 969-978.
5. Brown MA, Sirlin CB, Hoyt, DB, et al. Screening ultrasound in blunt abdominal trauma. *J Intensive Care Med* 2003; 18: 253-260.
6. Dolich MO, McKenney MG, Varela JE, et al. 2576 ultrasounds for blunt abdominal trauma. *J Trauma* 2001; 50: 108-112.
7. Lentz KA, McKenney MG, Nunez DB, et al. Evaluating blunt abdominal trauma: role for ultrasonography. *J Ultrasound Med* 1996; 15: 447-451.
8. Chambers JA, Pilbrow WJ. Ultrasound in abdominal trauma: an alternative to peritoneal lavage. *Arch Emerg Med* 1988; 5: 26-33.
9. Gruessner R, Mentges B, Duber C, et al. Sonography versus peritoneal lavage in blunt abdominal trauma. *J Trauma* 1989; 29: 242-244.
10. Forster R, Pillasch J, Zielka A, et al. Ultrasonography in blunt abdominal trauma: influence of the investigators' experience. *J Trauma* 1992; 34: 264-269.
11. Rozycki GS, Ochsner MG, Schmidt JA, et al. A prospective study of surgeon-performed ultrasound as the primary adjuvant modality for injured patient assessment. *J Trauma* 1995; 39: 492-498.
12. Shackford SR. Focused ultrasound examinations by surgeons: the time is now. *J Trauma* 1993; 35: 181-182.
13. Buzzas GR, Kern SJ, Smith RS, et al. A comparison of sonographic examinations for trauma performed by surgeons and radiologists. *J Trauma* 1998; 44: 604-608.
14. Rozycki GS, Shackford SR. Trauma ultrasound for surgeons. In: Staren ED, ed. *Ultrasound for the surgeons*. New York: Lippincott-Raven; 1997: 120-135.
15. Shackford SR, Rogers FB, Osler TM, et al. Focused abdominal sonogram for trauma: the learning curve of nonradiologist clinicians in detecting hemoperitoneum. *J Trauma* 1999; 46: 553-562.
16. Ma OJ, Mateer JR, Ogata M, et al. Prospective analysis of a rapid trauma ultrasound examination performed by emergency physicians. *J Trauma* 1995; 38: 879-885.
17. Schechter ML. Sensitivity, specificity, and predictive value. In: Troidl H, Mckneally MF, Mulder DS, Wechsler AS, McPeck B, Spitzer WO, eds. *Surgical research: Basic principles and clinical practice*, 3rd ed. New York: Springer; 1998: 257.
18. Gracias VG, Frankel HL, Gupta R, et al. Defining the learning curve for the focused abdominal sonogram for trauma (FAST) examination: Implications for credentialing. *The Am Surg* 2001; 67: 364-368.
19. Kimura A, Otsuka T. Emergency center ultrasonography in the evaluation of hemoperitoneum: a prospective study. *J Trauma* 1991; 31: 20-23.

20. Rozycki GS, Ochsner MG, Jaffin JH, et al. Prospective evaluation of surgeons' use of ultrasound in the evaluation of trauma patients. *J Trauma* 1993; 34: 516-526.
21. Smith RS, Kern SJ, Fry WR, et al. Institutional learning curve of surgeon-performed trauma ultrasound. *Arch Surg* 1998; 133: 530-536.
22. Lucciarini P, Ofner D, Weber F, et al. Ultrasonography in the initial evaluation and follow-up of blunt abdominal injury. *Surgery* 1993; 114: 506-512.
23. Thomas B, Falcone RE, Vasquez D, et al. Ultrasound evaluation of blunt abdominal trauma: Program implementation, initial experience, and learning curve. *J Trauma* 1997; 42: 384-390
24. Brooks A, Davies B, Smethhurst M, et al. Prospective evaluation of non-radiologist performed emergency abdominal ultrasound for haemoperitoneum. *Emerg Med J* 2004; 21: e5. Available from: URL: <http://www.emjonline.com/cgi/content/full/21/5/e5>.