

---

## RETAINED SURGICAL SPONGE: DIAGNOSIS WITH SONOGRAPHY-A CASE SERIES

Dr. Md. Murshed Ali. MBBS; M-Phil(NM); Ph.D <sup>1</sup>

### INTRODUCTION

A retained foreign body in the abdominal cavity following surgery is a continuing problem. Despite precautions, the incidence is grossly underestimated.

Retained foreign objects after surgery are associated with multiple major surgical procedures being performed at the same time and an incorrect instrument or sponge count.

The diagnosis of a retained surgical sponge was made by sonography in three patients. The plain abdominal radiograph were normal in all cases. In each of the three cases. Sonography disclosed a well-defined hypoechoic mass containing highly echogenic foci with a strong posterior shadow. In these cases, sonographic findings, together with a history of surgery, permitted the correct preoperative diagnosis of a retained foreign body.

There are many causes of pain in the abdomen which ultrasonography play a vital role to find out the causes.

This study was performed in the Centre for Nuclear Medicine and Ultrasound, Rangpur to find out the post-operative intra-abdominal foreign body.

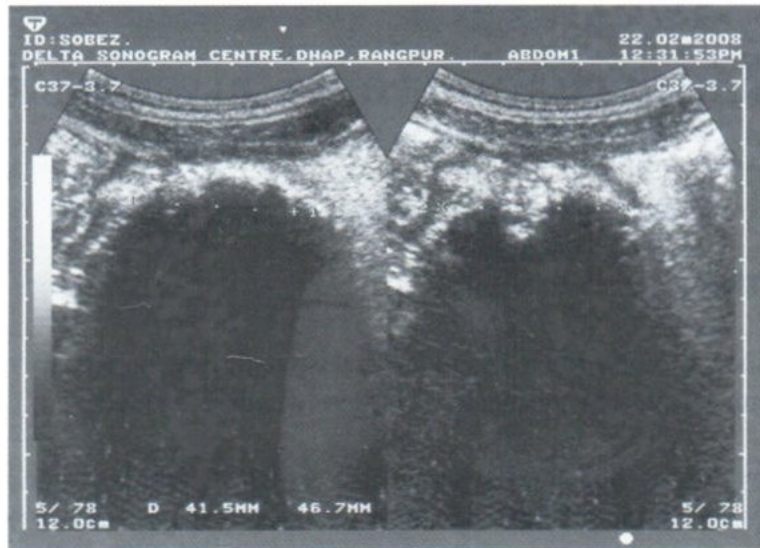
### CASE 1

A young lady of about 20 years admitted into the hospital with the complaint of constant pain of variable nature in the right lower abdomen and generalized weakness, weight loss, constipation, nausea and intermittent fever for the last six months. She had abdominal laparotomy for appendicular pathology. Her pulse was 76 min, B.P. was 115/70 mm of Hg. The patient was mild anaemic, but non icteric.

On palpation, deep tenderness was present in the right lower abdomen but no definite lump/mass felt in right lower abdomen. Her menstrual cycle was regular. Her plain x-ray of abdomen reveals nothing contributory. She was send for ultrasound scan. After adequate bowel preparation, ultrasound scan reveal a bright semi lunar echogenic structure casting dense posterior acoustic shadow in the right lower abdomen which does not consistent with others abdomino-pelvic organs.

---

<sup>1</sup> Senior Medical Officer and Director (Acting) Centre for Nuclear Medicine and Ultrasound, Dinajpur, Bangladesh.

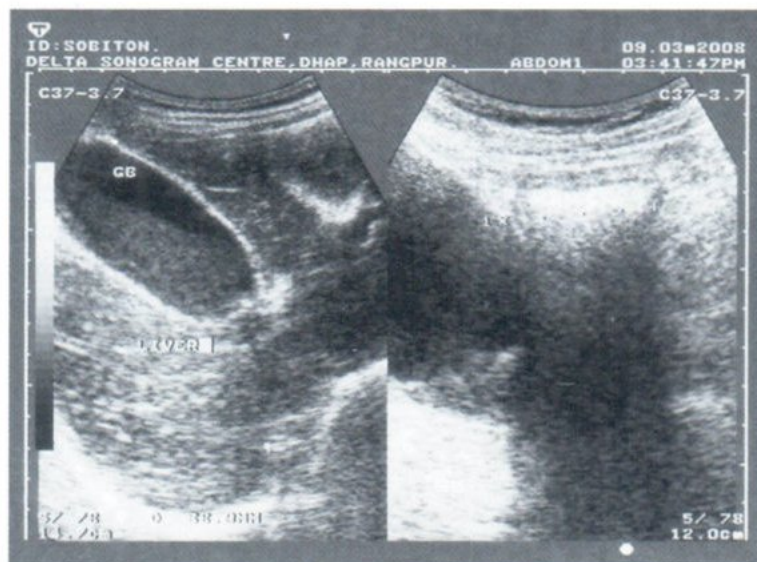


CASE 1

CASE 2

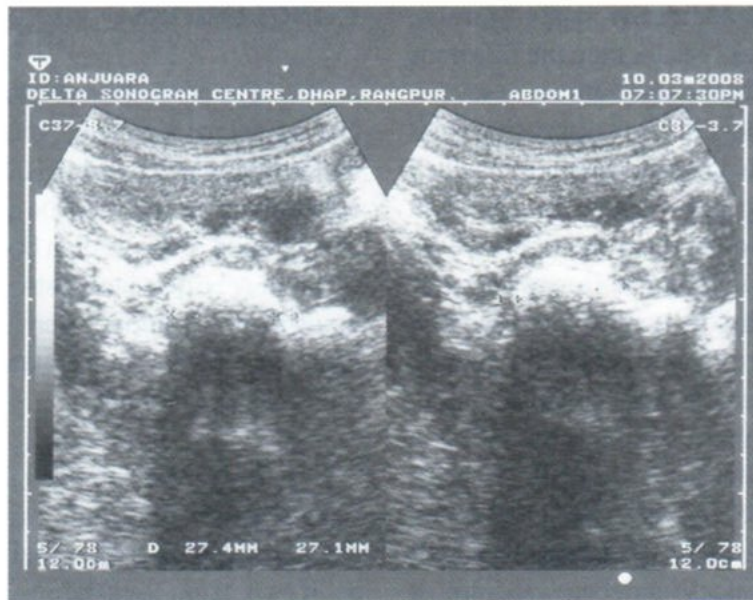
An women age about 39 years admitted into the hospital for abdominal hysterectomy and hysterectomy done accordingly. From the 7<sup>th</sup> post operative day she suddenly developed features of acute abdomen. Her pulse was 88 beat/min, B.P. was 145/85 mm of Hg, temperature 102<sup>o</sup> F. She was dehydrated, mild anemic but no jaundice. On palpation abdomen was distended, severely tender, more marked

in the left para-umbilical region. Her plain x-ray abdomen reveals sub-acute intestinal obstruction She was sent for ultrasound examination. Ultrasound scan reveals a large bright echogenic structure with a thin rim of hypoechoic collection around which does not consistent with other abdominal organ and was associated with distended loops of intestine.



CASE 2





**CASE 3**

### CASE 3

A man aged about 45 years admitted into the hospital with complaints of generalized weakness, gradual weight loss, nausea, and constant pain in right lower abdomen. He had a history of laparotomy for repairing of the perforation of abdominal hollow viscus in the last 3 months. His pulse was 78 /min, B.P. 130/80 mm of Hg, temperature was 99° F. He was mild anaemic but non-icteric. On palpation deep tenderness was present in the right lower abdomen. His plain x-ray abdomen reveals nothing contributory. He was sent for ultrasound scan. Ultrasound scan revealed a large irregular bright structure casting strong posterior acoustic shadow in the right lower abdomen above the level of umbilicus which does not consistent with other abdominal solid organs.

### MATERIALS AND METHODS

A detailed history was obtained and physical examination carried out. Ultrasounds were performed by using Toshiba Just Vision-400 Ultrasound machine using 3.5 to 5 MHz probes. Most of the patient had adequate bowel preparation for abdominal ultrasound.

### DISCUSSION

Retained surgical foreign body is seldom reported due to medicolegal implications. Awareness of this problem among surgeons and radiologists is essential to avoid unnecessary morbidity.

The diagnosis of retained surgical foreign body will continue to be a problem as long as nonabsorbable materials are used. The most common surgically retained foreign body is gauze.<sup>1</sup>

Since cotton sponges are inert. They do not undergo any specific decomposition of biomedical reaction.<sup>2</sup> Pathologically, however, two types of foreign-body reactions occur.<sup>3</sup> One is an aseptic fibrinous response that creates adhesions and encapsulation, resulting in a foreign-body granuloma. This occurred in one of our three cases. In the other variety, the response is exudative in nature and leads to abscess formation with or without secondary bacterial invasion. The development of an abscess represents an attempt by the body to extrude the foreign material, either externally or into a hollow viscus. This may lead to postsurgical complications such as fecal fistula or erosion and perforation into



adjacent viscera.<sup>1,2</sup> The exudative type of foreign-body granuloma appears earlier than the fibrinous type, because symptoms and signs are more severe. Radiologically, a whirl-like pattern on plain radiographs has been described as being characteristic of retained sponges.<sup>4</sup> This finding may be due to gas of an intestinal organ trapped between the fibers of the sponges. However, this finding is not always present. In this series, no abnormality was detected on plain abdominal radiographs of the two cases and another had features of sub-acute intestinal obstruction. In foreign-body granulomas, sonography shows a raniform mass with an echogenic center and hypoechoic rim. A central echogenic area represents the retained foreign body, which strongly attenuates the sound waves, thus creating an intense and sharply delineated acoustic shadow.<sup>5</sup> In these cases, a retained surgical sponge with granuloma or abscess formation must be differentiated from abscesses due to other causes.<sup>6</sup>

Despite the rarity of the reporting of a retained surgical sponge, this occurrence appears to be encountered more commonly than generally appreciated. Operating teams should ensure that sponges be counted for all vaginal and any incisional procedures at risk for retaining a sponge. In addition, the surgeon should not unquestioningly accept correct count reports, but should develop the habit of performing a brief but thorough routine post operative wound/body cavity exploration before wound closure. The strikingly similar outcome for most patients would argue for a standardized indemnity payment being made without the need for adversarial legal procedures.

Ultrasonography has paramount importance in investigating the cause of pain in the abdomen. Apart from its noninvasiveness nature and lack of radiation exposure, ultrasound can provide the information on the presence of post-operative intra-abdominal retained foreign body.<sup>7</sup>

## CONCLUSIONS

The clinical manifestations ranged from mild abdominal pain, palpable mass, persistent drainage and granuloma to intestinal obstruction secondary to adhesions or occlusion of the intestinal lumen because of migration of the foreign body and intraabdominal sepsis may be detected post-operatively. Despite this being a rare situation, when it happens it presents as a very serious problem to patients with high rates of morbidity and mortality.

Prevention remains the key to the problem. Ultrasound is the initial procedure of choice for detection of intra-abdominal retained foreign body, as it is easier, available, hazardless and cost effective.

## REFERENCE

1. Williams RG, Bragg DG, Neison JA. Gossypoboma- The problem of the retained surgical sponge, *Radiology* 1978; 129: 323-326.
2. Sturdy JH, Baird RM, Gerein AN. Surgical sponges: a cause of granuloma and adhesion formation *Ann Surg* 1967; 165: 128-134.
3. Olnick HM, Weens HS, Rogers JV Jr. Radiological diagnosis of retained surgical sponges. *JAMA* 1955; 159: 1525-1527.
4. Robinson KB, Levin EJ, Erosion of retained surgical sponges into the intestine. *AJR* 1966; 96: 339-343.
5. Mason LB. Migration of surgical sponges into small intestine. *JAMA* 1968; 205: 938-939.
6. Kressel HY, Filly RA. Ultrasonographic appearance of gas-containing abscesses in the abdomen, *AJR* 1978; 130: 71-73.
7. Chan MY, Tan C, Chiu MT, et al; Alvarado score: an admission criterion in patients with right iliac fossa pain. *Surgeon*. 2003 Feb; 1(1): 39-41. [abstract]